



---

## HISTOLOGICAL AND ULTRASTRUCTURAL STUDY OF BDUCTOR HALLUCIS MUSCLE IN CHILDREN WITH DIOPATHIC CLUB FOOT AND IN CONTROLS

S.A El Sherbiney

*Departments of Histology and Orthopedic Surgery*

A.S EL Lakany

*Departments of Orthopedic Surgery\*, Faculty of Medicine, Mansoura University, Egypt.*

M.R EL Lakany

*Departments of Orthopedic Surgery\*, Faculty of Medicine, Mansoura University, Egypt.*

Follow this and additional works at: <https://mmj.mans.edu.eg/home>

---

### Recommended Citation

El Sherbiney, S.A; EL Lakany, A.S; and EL Lakany, M.R (2001) "HISTOLOGICAL AND ULTRASTRUCTURAL STUDY OF BDUCTOR HALLUCIS MUSCLE IN CHILDREN WITH DIOPATHIC CLUB FOOT AND IN CONTROLS," *Mansoura Medical Journal*: Vol. 30 : Iss. 1 , Article 4.

Available at: <https://doi.org/10.21608/mjmu.2001.126992>

This Original Study is brought to you for free and open access by Mansoura Medical Journal. It has been accepted for inclusion in Mansoura Medical Journal by an authorized editor of Mansoura Medical Journal. For more information, please contact [mmj@mans.edu.eg](mailto:mmj@mans.edu.eg).

# HISTOLOGICAL AND ULTRASTRUCTURAL STUDY OF ABDUCTOR HALLUCIS MUSCLE IN CHILDREN WITH IDIOPATHIC CLUB FOOT AND IN CONTROLS

*By*

El Sherbiney, S.A, EL Lakany, A.S and EL Lakany, M.R.\*

*From*

*Departments of Histology and Orthopedic Surgery\*,  
Faculty of Medicine, Mansoura University, Egypt.*

## ABSTRACT

Idiopathic congenital club foot is a birth defect that is marked primarily by a deformed ankle and heel as well as the forepart of the foot, that gives the foot a characteristic "club - like" appearance. Thus the infant's foot points downward and inward.

We evaluated in the present work the abductor hallucis muscle of 9 children with club feet, age (9 months to 48 months). Histological examination of muscle sections from club feet cases revealed histopathologic changes in the form of marked variation of muscle fiber size, multiple vacuolation of the sarcoplasm in some fibers and wide separation of muscle fibers with increased connective tissue component in between them.

The results of the current study

demonstrated that, succinic dehydrogenase enzyme activity in the muscle fibers of club feet cases was markedly decreased. Inhibition of that enzyme activity indicates impaired muscle energy metabolism due to alteration of mitochondrial structure and function.

Transmission electron micrographs revealed wide separation of myofibrils of club feet cases with focal areas of degeneration. In addition, disruption of myofibrils and derangement of Z bands were noticed. Mitochondria showed bizarre shape and distribution in some fibers with increased connective tissue components in between muscle bundles. These affected fibers were surrounded by normal ones.

Statistically, the percentage of

type I fibers was significantly higher in club foot muscles than in control cases.

The myopathy detected in club foot cases was considered a congenital type that resulted from neuromuscular abnormality. The early detection of the type and degree of muscle affection in idiopathic club foot might be of prognostic value and a way of prevention of recurrence after operative correction.

## INTRODUCTION

Club foot, a relatively frequent congenital malformation, may be associated with several genetic syndromes or other malformations, or may appear as an isolated idiopathic anomaly [1].

Bronshtein et al [2] described the intrauterine development of clubfeet subsequent and in parallel to fetal hydrocephalus formation as followed by serial transvaginal sonographic scans (at 11 - 16 weeks gestation). The latter authors suggested, the possibility of a causal relationship between the central nervous system malformation and the development of club feet.

Although not life - threatening, club

feet, a non - traumatic deviation of the foot, makes a strong impact on the infant, parents, and family. Nursing care needs to focus on emotional support of the family and education regarding the diagnosis, treatment plan, and family care of an infant in a cast [3].

Electrophysiological studies were carried out on idiopathic club feet with residual deformities after conservative or operative treatment. The results of these studies support the theory that muscle imbalance is an aetiological factor in idiopathic congenital club foot [4].

Maffuli et al [5] reported that the histochemical composition of the abductor hallucis muscle was investigated in 13 children with unilateral idiopathic clubfoot. Muscle biopsies from the club foot side showed an increase in their connective tissue content. In addition, the affected side showed a significant higher percentage of type 1 fibers than other fiber types, whereas the average capillary density and capillary to fiber ratio were significantly lower.

The histochemical composition of the abductor hallucis (AH) muscle

was investigated in 39 children with idiopathic club foot (CF). The percentage of type 1 fibers was significantly higher than in controls. The relative predominance of type 1 fibers could be due to immobilization, passive stretching, or by an unknown neural factor [6].

None of these previously mentioned interpretations could be proven. As a consequence, the present study was undertaken to further investigate the histological, histochemical and ultrastructural features of the (AH) muscle of children with idiopathic club feet in comparison with control muscles, in a trial to find out the possible aetiology and the relationship between the histopathological and histochemical findings as well as the relationship between these changes and the severity of the deformity.

## **MATERIAL AND METHODS**

### ***Samples:***

This study involved muscle biopsies from 9 children with club feet deformity. The age of these children ranged from 9-48 months.

Out of these 9 feet, 4 feet did not respond to any previous conservative measures while in 5 feet, there were

recurrence of the deformity after previous surgical treatment.

The biopsies were taken from the abductor hallucis (AH) muscle during the operative correction of the deformity by the technique described by Carroll [7].

Four control muscle samples were obtained during the operative treatment of fractures in children.

### ***Histological study:***

Small pieces from all the samples were fixed in 10% neutral formalin, embedded in paraffin, and cut into 6  $\mu\text{m}$  sections that were routinely stained with Hx & E.

### ***Histochemical study:***

Fresh unfixed small pieces from all the samples were cut by the cryostat at 15 $\mu\text{m}$  sections which were stained for demonstration of succinic dehydrogenase enzyme activity Nachlas et al., method, after pearse [8].

### ***Ultrastructural study:***

Parts from all the muscle samples 3mm thick were fixed in a mixture of 2% paraformaldehyde and 2% glutaraldehyde in 0.1 M phosphate buffer (PH 7.3). They were stored in the



fixative for 4 hours at 4°C, then washed in cacodylate buffer. They were post fixed in 1% osmium tetroxide, dehydrated and embedded in Araldite. Semithin sections (0.5 µm) were stained with toluidine blue and examined by the light microscope.

Ultrathin sections (200 - 400 Å) were cut and stained with uranyl acetate and lead citrate for transmission electron microscopic examination

#### **Statistical study:**

The mean diameter of human muscle fibers varies with age and with athletic training [9]. In normal adult the fiber diameter is between 40 - 80 µm in males and 30 - 70 µm in females. At birth, the mean fiber diameter is 15 µm and it increases gradually to reach 40 µm by 10 years [10].

The diameter of individual muscle fibers for a randomly chosen (40 to 96) different sized muscle fibers per each diseased and control sample was measured using a calibrated micrometer. The data obtained were recorded, tabulated and statistically analysed. The frequency table, cross tables, and Chi-square test were used to determine the percentage of each type of muscle fibers and any change

in their average percentage in club foot cases in comparison with control cases.

## **RESULTS**

### ***Histological findings***

Haematoxylin and eosin stained sections of muscle biopsy from the abductor hallucis muscle of club foot children showed wide separation of muscle fibers that differ from the normally tightly packed polygonal eosinophilic healthy control ones (Fig. 3, 6, 1, 2). Individual muscle fibers of idiopathic club foot cases showed variation in muscle fiber size. Some of which, showed a moth eaten change in the form of pale unstained areas in the darkly stained sarcoplasm of muscle fibers (Fig. 3,4,5).

The extent of histopathological changes and vacuolation of skeletal muscle fibers differs in severity among the studied cases. In five samples which were taken from recurrent clubfoot cases, the muscle fibers were severely affected. The vacuoles were not only affecting a large number of muscle fibers bundles, but they were also so large that they occupied the major bulk of the muscle fibers leaving

only a little rim of acidophilic cytoplasm at the periphery of each muscle fiber (Fig. 7). In club feet cases the affected muscle bundles were surrounded by healthy intact muscle fibers (Fig. 3 , 5 , 6)

#### ***Histochemical results:***

Succinic dehydrogenase enzyme activity was strong positive in muscle fibers of the control sections of abductor hallucis muscle. In this case, muscle fibers showed three types: darkly stained fibers with strong positive enzyme activity, pale stained fibers with very weak enzyme activity, and fibers with intermediate enzyme activity (Fig. 8 & 9).

In cases with idiopathic club feet, succinic dehydrogenase enzyme activity was markedly inhibited in all muscle fiber types compared to control cases (Fig. 10, 11).

#### ***Ultrastructural results:***

Semithin sections stained with toluidine blue demonstrated the skeletal muscle fibers of control abductor hallucis muscle. These control muscle fibers appeared closely coapted together with little amount of connective tissue and relatively large amount of blood capillaries in between them

(Fig. 12, 13).

On the other hand, sections of club feet cases showed wide spacing of muscle fibers, marked variation in the muscle fiber size with many angulated and hypertrophic muscle fibers (Fig. 14, 15). Blood capillaries in between individual muscle fibers were scanty in sections of club feet cases in comparison with control sections (Fig. 14, 12).

Transmission electron microscopic pictures of control abductor hallucis muscle fibers demonstrated the myofibrils enclosed within a smoothly wavy sarcolemma and had characteristic fusiform subsarcolemmal nuclei with prominent electron dense nucleoli (Fig. 16). The sarcoplasm showed the characteristic myofilaments which were oriented longitudinally in register with one another (Fig. 16, 17). Mitochondria were located in the subsarcolemmal region and in between myofibrils (Fig. 17, 18, 19 ). In addition, a well developed Golgi apparatus was seen near the nucleus (Fig. 19).

Electron micrographic pictures of the abductor hallucis muscle of idiopathic club feet cases revealed that,

the sarcolemma was wrinkled. The myofibrils exhibited either, slight widening of the interfibrillar spaces or disruption of focal areas of myofilaments (Fig. 20, 21). Focal disposition of contractile element was noticed with partial disappearance of regular banding pattern of myofibrils and derangement of Z bands (Fig. 22, 23). Mitochondria showed many abnormal configurations in the form of elongation, loss of regular cristae and abnormal pattern of distribution (Fig: 22, 23, 24)

The above mentioned abnormal muscle fibers were surrounded by some muscle fibers of normal structure (Fig. 20).

The TEM revealed also an increase in the connective tissue content of muscle fibers of abductor hallucis muscle from the club foot cases with marked increase in collagen fibers in the perimysium (Fig 21, 24, 25)

#### **Statistical results:**

The cross diameter of the muscle fibers of abductor hallucis muscle from club foot cases had a mean diameter of  $25.67 \mu\text{m} \pm 0.16$  and a range between 11 - 49  $\mu\text{m}$  (table: 1). In control cases, the mean diameter was  $27.31 \pm 0.25$  while the range of their diameter was between 22 - 46  $\mu\text{m}$ . Thus this statistical analysis reveals a significant decrease of the diameter of muscle fibers of club foot cases. In addition, the muscle fibers of club foot cases whose diameter was measured in the current study were composed of 369 (61.2%) of type I fiber with cross diameter between 11 - 27  $\mu\text{m}$  and 234 (38.8%) of type II (with diameter more than 27  $\mu\text{m}$ ) (table: 2).

In control cases the muscle fibers were comprised of 132 (48%) of type I fibers and 143 (52%) of type II fibers (table: 2). These results reveal a significant increase in type I fibers in club foot cases.



**Table (1) :** Diameter of muscle fibers among the studied groups

	Cases (n = 9)	Control (n = 4)
Mean	25.67	27.31
SE	0.16	0.25
Range	(11 - 44)	(22 - 48)

Test of significance

$$T = 4.71$$

$$P < .001^{***}$$

**Table (2) :** Percentage of types of muscle fibers of the studied groups

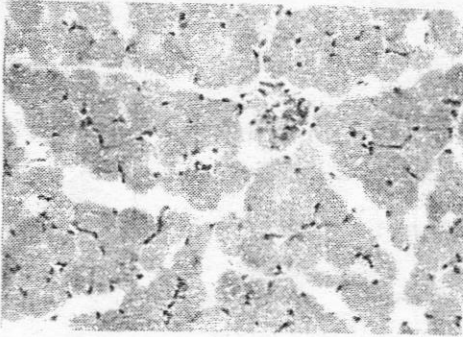
	Cases		Control		Total	
	No	%	No	%	No	%
Type I	369	61.2	132	48	501	57.1
Type II	234	38.8	143	52	377	42.9
Total	603	100	275	100	878	100

Test of significance

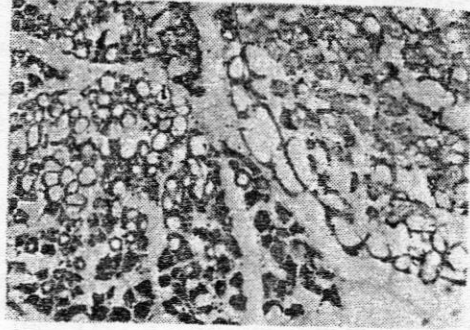$$\chi^2 = 13.41$$

$$P < .001^{***}$$

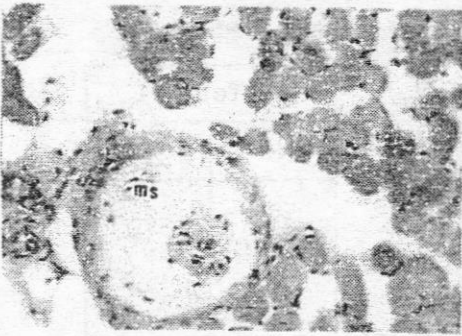




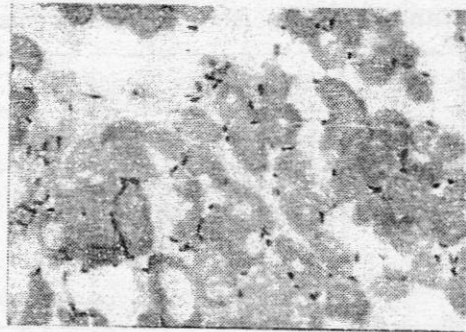
**Fig. (1):** A photomicrograph of a control section of abductor hallucis muscle. It shows the nearly coapted muscle fibers having acidophilic cytoplasm. (Hx. & E.; X 250).



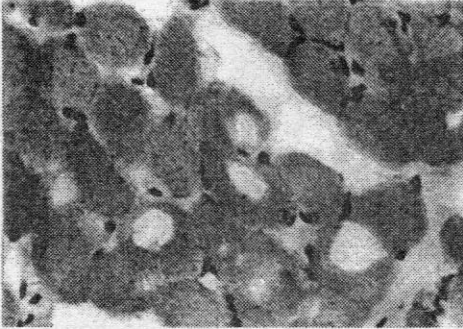
**Fig. (3) :** A photomicrograph of a paraffin section from a cases of club foot. The majority of muscle fibers have abnormal structure in the form of multiple small vacuoles (s) or a single large vacuole (L). (Hx. & E.; X 100).



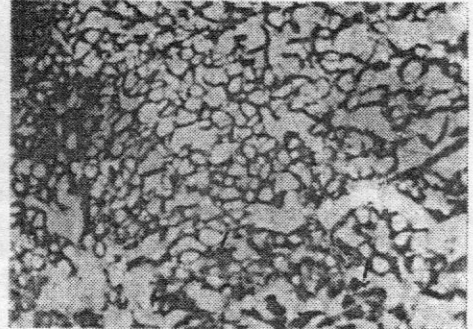
**Fig. (2) :** A photomicrograph of a control section showing the skeletal muscle fibers separated with connective tissue elements containing a muscle spindle (ms). (Hx.&E.;X250).



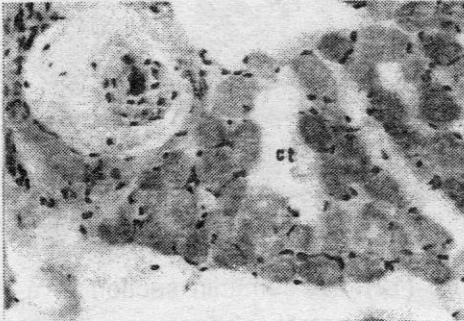
**Fig. (4) :** A photomicrograph of a case of club foot. The muscle fibres are moderately affected in the form of cytoplasmic vacuolation of different numbers and sizes. (Hx. & E.; X 250).



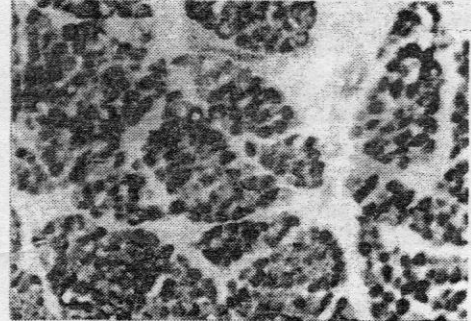
**Fig. (5) :** A photomicrograph of a club foot case. It demonstrates that the part of the muscle fiber containing the vacuole is completely devoid of myofibrils and contains only very thin threads of cytoplasm. (Hx. & E.; X 400).



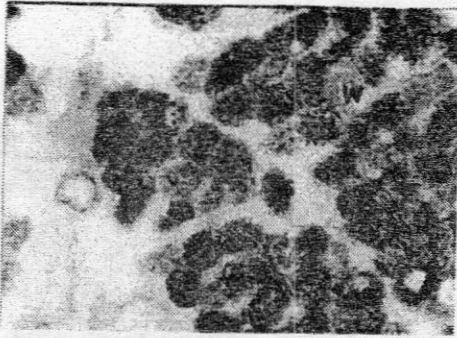
**Fig. (7) :** A photomicrograph of a recurrent case of club foot. The muscle fibers are severely affected. The majority of muscle fibers contain large vacuoles. Few number of healthy normal muscle fibers are detected (arrows). (Hx. & E.; X 100).



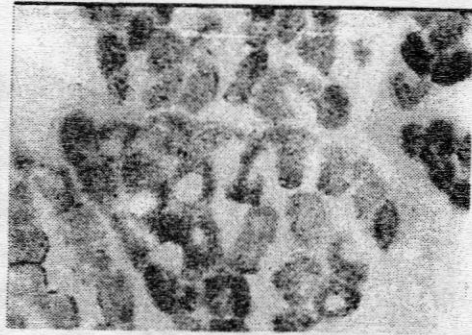**Fig. (6) :** A photomicrograph of a moderately affected club foot case. It shows few number of affected fibers surrounded by many healthy ones. However these fibers are separated by wide areas of connective tissue (ct) (Hx. & E.; X 250).



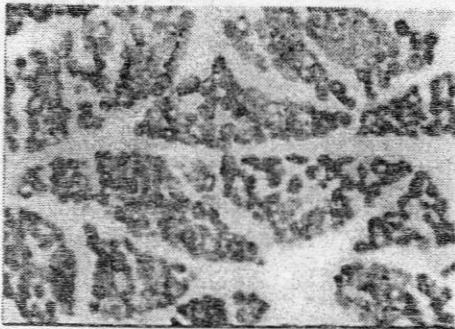**Fig. (8) :** A photomicrograph of a normal abductor hallucis muscle. It shows strong succinic dehydrogenase enzyme activity. (succinic dehydrogenase N.B.T method; X 100).



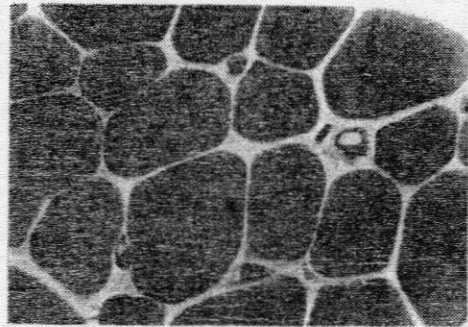
**Fig. (9) :** A photomicrograph of a cryostat section of control case. Here some muscle fibers exhibit strong enzyme activity (S), another group of muscle fibers show moderate enzyme activity (M) while others exhibit weak enzyme activity (W). (Succinic dehydrogenase N.B. T method; X 250).



**Fig. (11) :** A photomicrograph of a fresh unfixed section of a club foot case. It shows inhibition of enzyme activity in all muscle fiber types if compared with the control section. (Succinic dehydrogenase N.B.T method; X 250).




**Fig. (10) :** A photomicrograph of a fresh unfixed section of abductor hallucis muscle from a club foot case it shows inhibition of succinic dehydrogenase enzyme activity if compared with control section. (Succinic dehydrogenase N.B.T method; X 100).

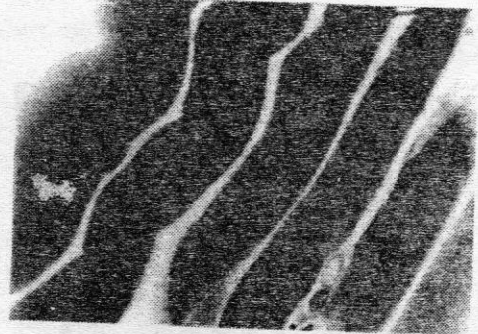


**Fig. (12) :** A semithin section of a control abductor hallucis muscle. It shows small type ( 1), Large Type (2B) and medium sized type (2A) fibers in the normal structure and average percentage. (Toluidine blue; X 1000).

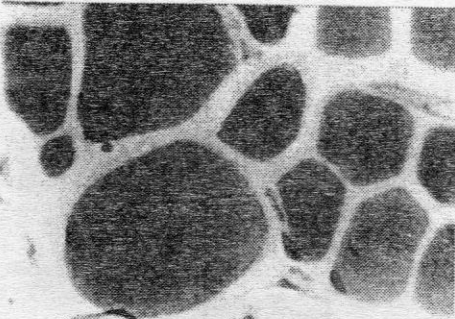




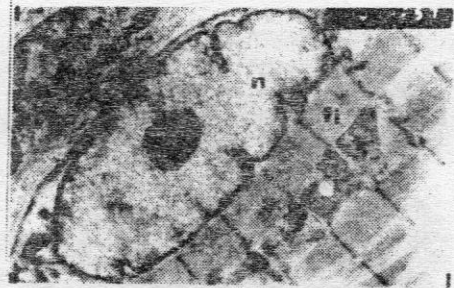**Fig. (13) :** A semithin section of a control abductor hallucis muscle. The muscle fibers are closely packed with minimal amount of endomysium containing blood vessels (bv) .  
(Toluidine blue; X 1000).



**Fig. (15) :** A photomicrograph of a semithin section from a mildly affected club foot case. The muscle fibers are separated from each other with variation in fiber diameter.  
(Toluidine blue; X 1000).



**Fig. (14) :** A photomicrograph of a semithin section of a mildly affected case of club foot. The muscle fibers are widely separated from each other and exhibit marked difference in diameter.  
(Toluidine blue; X 1000).

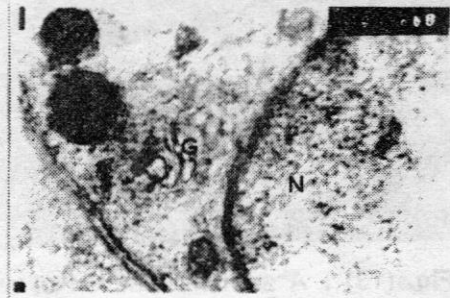

**Fig. (16) :** An electron micrograph of a longitudinal section of a control abductor hallucis muscle. It shows the characteristic subsarcolemmal nucleus (n) with prominent nucleolus. The myofibrils (exhibit the typical striation and interfibrillar mitochondria).  
(Toluidine blue; X 10000).

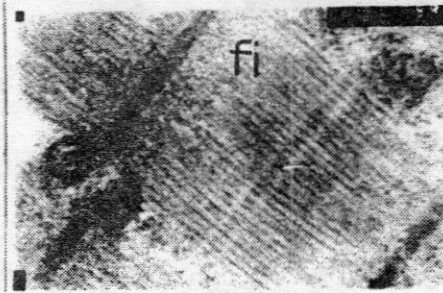




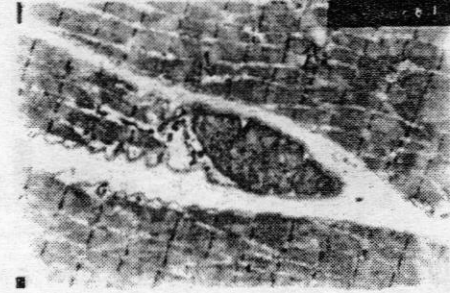
**Fig. (17) :** An electron micrograph of a control case. It shows the normal structure of myofibrils and the striation here is typically in register. Inter-fibrillar mitochondria are regularly distributed.  
(TEM; X 13,000).



**Fig. (19) :** An electron micrograph of a control case. It demonstrates the nucleus (N), a Golgi apparatus (G) and mitochondria (M).  
(TEM; X 50,000).



**Fig. (18) :** An electron micrograph of a control case. It shows normal interdigitation of actin and myosin myofilaments (fi)  
(TEM; X 50,000).



**Fig. (20) :** An electron micrograph of a club foot case. It shows mild affection of the muscle fibers in the form of wrinkling of the sarcolemma, abnormal elongated mitochondria and small degenerated areas (arrows).  
(TEM; X 5,000).

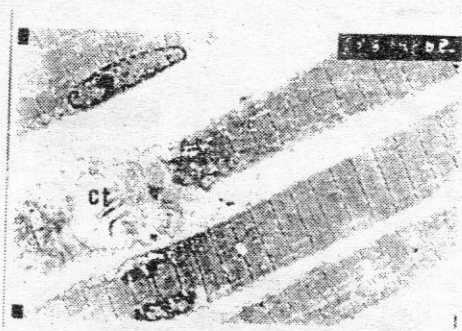


Fig. (21) : An electron micrograph of a club foot case. The muscle fibers are widely separated with larger amount of connective tissue elements (ct) in between them. (TEM; X 2,500).

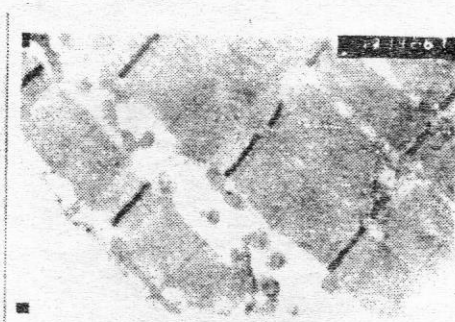

Fig (22) : An electron micrograph of a club foot case. It shows vacuolated areas interrupting the normal arrangement of myofibrils and interruption of the Z lines. The mitochondria are abnormally distributed. (TEM; X 15,000).

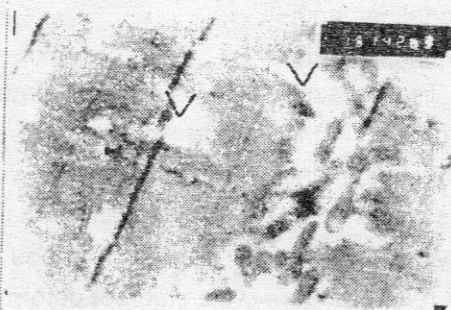
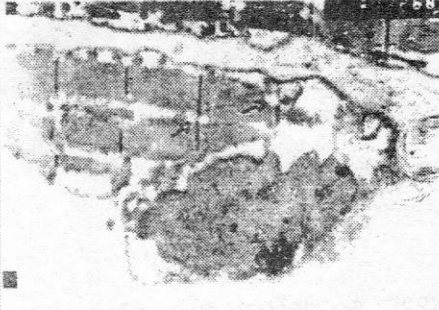
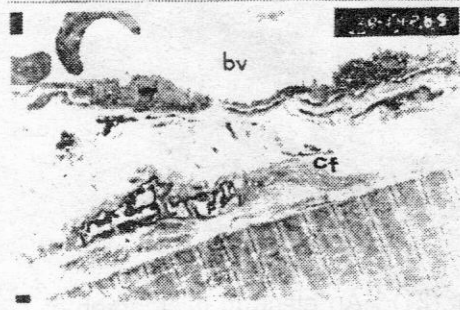


Fig. (23) : An electron micrograph of a club foot case. The muscle fibers contain many vacuolated (v) areas interrupting the regular arrangement of myofilaments and Z lines. Mitochondria exhibit abnormal shape and arrangement. (TEM; X 15,000).



**Fig. (24) :** An electron micrography of a club foot case. It shows moderate degree of affection in the form of many degenerated vacuolated areas (arrows) and mitochondria of abnormal shape and distribution (TEM; X 7500).



**Fig. (25) :** An electron micrograph of a club foot case. It reveals a large amount of collagen fibers (cf) inbetween the mildly affected muscle fibers and the blood vessel (bv.).  
(TEM; X 3000).

## DISCUSSION

Congenital idiopathic talipes equinovarus (club foot) is a complex and challenging entity [11]. The development of the human foot from the eighth to the twenty - first intrauterine week in 147 fetuses was studied ultrasonographically by kawashima and Uhthoff, [12]. Their results documented a stage of "physiological club foot" characterized by a medial deviation and plantigrade orientation of talar neck and head during the ninth week of intrauterine life. However, by the eleventh week, the

foot assumes a normal position.

Unilateral club foot is somewhat more common than bilateral club foot and may occur as an isolated defect or in association with other disorders such as chromosomal aberrations, cerebral palsy and spina bifida. Infantile clubfoot deformity is painless and correctable with early diagnosis and prompt treatment [13]. Some physicians perform physiotherapy and splints for treatment of idiopathic club foot, but of few use. Operative treatment is usually indicated at an age



ranging from 4 to 15 months [14] and [15].

Many genetic studies proposed an environmental and genetic components to the etiology of idiopathic club foot. Comprehensive work by Lachmiller et al [16]. was undertaken to assess the role of causal factors in the development of club foot. They suggested the potential role of a gene or genes operating in high - risk families to produce this foot deformity.

Antenatal sonographic examination of 6351 pregnant women, all underwent serial transvaginal ultrasound scanning for detection of suspected fetal anomalies was undertaken (over the period 1992 - 1998). This study revealed a total of 235 fetuses with hydrocephalus. Furthermore the latter study detected 41 cases with club feet, 14 cases of them were isolated while the remaining 27 were associated with neural tube defects [17].

Feet with abnormal muscle histology had a significantly greater incidence of recurrence of the deformity requiring reoperation [18]. This coincides with our findings since the samples involved in this study were obtained from 4 feet that did not respond

to any previous conservative measures and from 5 feet with recurrent deformity.

The collagen structure in the affected muscles in different types of club feet was studied by Van der sluijs and Pruys [19]. The latter authors analysed modification and crosslinks in collagen fibers and their possible relation with clinical stiffness of club foot deformity. Their findings indicated normal structure of collagen molecules and normal alignment of collagen molecules within the fibrils. However, Maffulli et al. [5] reported that, the muscle biopsies from the club foot side showed an increase in their connective tissue content together with a significant higher percentage of type 1 fibers. Whereas, the average capillary density and capillary to fiber ratio were significantly lower .

The results of our current work revealed a noticeable fiber size variation and many muscle fibers showed multiple vacuolation within their sarcoplasm. There was also wide separation of muscle fibers with relative increase of perimysial connective tissue in abductor hallucis muscles of club feet cases. Our histopathological results are in agreement with the



previous work done by Bensahel et al [14] who studied 64 children with idiopathic club feet fifty percent of these biopsies demonstrated abnormal muscle fiber morphology, classified as congenital fiber - type or fiber size variation.

Succinic dehydrogenase (Sd) enzyme activity was markedly decreased in muscle fibers from club feet cases in comparison with control ones. Inhibition of (Sd) enzyme activity in muscles of club feet cases may be explained by the previous findings of Swash and Schwartz, [9], Weller et al., (20) and Keiichi et al., (21). The latter authors reported that, the congenital myopathy found in affected muscles of congenital club feet cases is accompanied by muscle degeneration which was thought to be due to impaired muscle energy metabolism due to altered mitochondrial respiration.

Transmission electron micrographs of abductor hallucis muscles of club feet cases demonstrated some ultrastructural abnormalities. Some areas of the myofibril appeared disorganized with disruption of myofilaments with loss of the typical banding pattern. Various forms of mitochondri-

al abnormality was observed in the form of elongation, and abnormal distribution. There was an increase of the collagen fibers in the perimysium. However, these ultrastructural changes were detected in some fibers while, the surrounding fibers showed normal structure without bizarre - shaped mitochondria nor degenerative changes. Our ultrastructural findings were in accordance with the work done by Kranicz et al [22] who carried out an electron microscopic analysis of the so called "club foot" muscles. They observed minor gross changes in the affected muscles in the form of increased collagen fiber content and large number of fibroblast - like cells. Further more Zimny et al [23] and Gosztonyi et al [24] reported that the ultrastructural analysis of the calf muscles in club foot revealed only minor fine structural changes. The changes found were not present in every area of the muscles, but were surrounded by fields of muscle fibers having normal structure.

Statistically, the percentage of type 1 (slow twitch, tonic) fibers was significantly higher in club feet muscles than in control cases in the present work. This relative predominance of type I fibers could be due to

immobilization, passive shortening or due to an unknown neural factor. The latter finding was recorded by Cooper and Dietz [25] and Czukonyi et al [26].

In conclusion the combination of findings of the current work had demonstrated a congenital type of myopathy affecting some myofibrils of the abductor hallucis muscles of club feet. The severity of histopathological changes detected in our samples could explain failure of the primary conservative treatment measures in some cases and the recurrence in others. Therefore, we think that thorough understanding of the pathoanatomy of these deformed feet may be of prognostic value. This also could be helpful in decreasing the rate of recurrence by correcting the deformity by the operative technique that could be suitable with the severity of the case from the start.

## REFERENCES

- 1- Aronson, J. and Puskarich, C.L. (1998) : Deformity and disability from treated clubfoot. *J. Pediatr. orthop.*, 10: 1, 100 - 109.
- 2- Bronshtein, M.; Liberson, A.; Liberson, S. and Blumenfeld, Z. (1992) : Clubfeet associated with hydrocephalus, new evidence of gradual dynamic development in utero. *Am. J. Med. Genet.*, 79: 2, 97 - 102.
- 3- Kyzer, S.P. (1992) : Congenital idiopathic clubfoot. *J. orthop. Nurs*, 10: 4, 11 - 23.
- 4- Feldbrin, Z.; Gilai, A.N.; Kermosh, O.; Kramer, U. and Wientroub, S. (1995) : Muscle imbalance in the aetiology of idiopathic club foot. An electromyographic study. *J. Bone Joint surg. Br*, 77: 4, 596 - 601.
- 5- Maffulli, N.; Capasso, G.; Testa, V. and Borrelli, L. (2000) : Histochemistry of the triceps surae muscle in idiopathic congenital clubfoot. *J. Foot Ankle*, 13: 2, 80 - 94.
- 6- Sirca, A.; Erzen, I. and Oecak, F. (1990) : Histochemistry of abductor hallucis muscle in children with idiopathic club foot. *J. Pediatr. orthop.*, 10:

4, 477 - 482.

**7- Carroll, N.C. (1987)** : Congenital club foot : Pathoanatomy and treatment. AAOS Inst. Course lect., 36--117.

**8- Pearse, A.G.E., (1968)** : Histochemistry theoretical and applied, 3rd ed. Churchill Livingstone, Edinburgh, London, and New York.

**9- Swash, M. and Schwartz, M. (1981)** : Neuromuscular diseases. A practical approach to diagnosis and management. Springer, Berlin, Germany.

**10- Brooke, M. H. and Engel, W.K. (1989)** : The histographic analysis of human biopsies with regard to fiber types. New England J. of Medicine, 292: 403 - 415.

**11- Biakesiec, T.J. (1999)** : Congenital idiopathic talipes equinovarus (clubfoot). Current concept. J. clin. Pediatr. Med. Surg., 14: 1, 9 - 56.

**12- Kawashima, T. and Uthoff, H.K. (1990)** : Development of the foot in prenatal life in relation to idiopathic club foot. J. Pediatr. orthop., 10: 2, 232 - 247.

**13- Kyzer, S.P. and stark, S.L. (1995)** : Congenital idiopathic club foot deformities. AORN. J., 61: 3, 492 - 506. Center for cases Management, south Natick, Mass, USA.

**14- Bensahel, H.; Catterall, A. and Dimeglio, A. (1990)** : Practical applications in idiopathic clubfoot; a retrospective multicentric study in EPOS. J. Pediatr. orthop., 10: 2, 186 - 198.

**15- Paton, R.W. and Freemont, A.J. (1999)** : A clinicopathological study of idiopathic talipes equinovarus. J. R call surg. Edinb., 38: 2, 108 - 119.

**16- Lachmiller, C.; Johnston, D.; Scott, A.; Risman, M. and Hecht, J.T. (1998)** : Genetic epidemiology study of idio-



- pathic talipes equinovarus.  
Am. J. Med. Genet, 79: 1,  
80 - 95.
- 17- Pagnatta, G.; Maffulli, N.;  
Aureli, S.; Maggi, E.; Mari-  
ani, M. and Yip, K.M.  
(1998) : Antenatal sono-  
graphic diagnosis of club  
foot: a six - year experience.  
J. Foot Ankle surg., 35: 1,  
67 - 79.
- 18- Loren, G. J.; Karpinski, N.C.  
and Mubarak, S.J. (1998) :  
Clinical implications of club  
foot histopathology. J. Pedi-  
atr. orthop., 18: 6, 765 - 769.
- 19- Van der sluijs, J.A. and pruijs,  
J.E (1999) : Normal col-  
lagen structure in the  
posterior ankle capsule in  
different types of club feet.  
J. Pediatr. Orthop., 8: 4,  
261 - 273.
- 20- Weller, R.O.; Swask, M.; MC Iel-  
lan, D.L. and Scholtz, C.L.  
(1983) : Clinical neuropa-  
thology. Springer, Berlin.
- 21- Keiichi, K.; Mosaru, K.; Sonoda,  
Y.; Yoshidome, H.; Nak-  
agawa, H.; Fujiyama, J.;  
Higuchi, I. and Osame,  
M. (1998) : Myopathy in-  
duced by HMG - COA  
reductase inhibitors in rab-  
bits; a pathological electro-  
physiological and bio-  
chemical study, J. of  
Toxicol, and applied phar-  
macol., 152: 99 - 106.
- 22- Kranicz, J.; Trombitas, K. and  
Szabo, G. (1991) : Results  
of ultrastructural analysis  
of the calf muscles in club  
foot. J. orthopedics, 14: 1,  
73 - 85.
- 23- Zimny, M.L.; Willing, S.J; Rob-  
erts, J.M. and DiAmbrosia,  
R.D. (1985) : An electron-  
microscopic study of the fas-  
cia from the medial and lat-  
eral sides of clubfoot. J.  
pediatr. orthop., 5: 5, 577 -  
581.
- 24- Gosztanyi, G.; Dorfonuller,  
K.S; Sparmann, M. and  
Sisenchenk, A., (2000) :  
Morphometric and ultra-  
structural study of flexor  
group muscles in congenital  
idiopathic club foot. J.



pathol. Res. Pract, 185: 5, 790 - 804.

**25- Cooper, D. M. and Dietz, F.R. (1995) :** Treatment of idiopathic clubfoot. J. Bone Joint surg Am., 77: 10, 1477 - 1489.

**26- Czukonyi, Z.; Desgrippes, Y. and Guillaume, A. (1998) :** Results of physical therapy for idiopathic clubfoot; a long - term followup study. J. Peditaer. orthop., 10: 182 - 194.

## دراسة هستولوجية وللتركيب الدقيق للعضلة المبعدة للإصبع الأكبر في الأطفال غير المصابين أو المصابين بالقدم القدفاء

د. سناء أحمد الشرييني د. أمانى سامح اللقانى د. رضا سامح اللقانى\*  
أقسام الهستولوجى وجراحة العظام\* - كلية الطب - جامعة المنصورة

تعد القدم القدفاء الوراثية عيب خلقى يتميز بتشوه الكاحل وكعب القدم مما يعطى القدم شكلاً مغلبياً مميزاً وبذلك تتجه قدم الوليد إلى أسفل وللداخل .

ولقد قمنا فى الدراسة الحالية بتقييم العضلة المبعده للإصبع الأكبر لتسعة أطفال مصابين بالقدم القدفاء تتراوح أعمارهم بين ٩ شهور و ٤٨ شهر. وقد أظهر الفحص الهستولوجى للقطاعات المأخوذة من عضلات الأطفال المصابين تغيرات هستوباثولوجية فى شكل إختلاف واضح فى حجم الألياف وظهور فجوات متعددة فى بعضها وزيادة نسبة النسيج الضام بينها واتساع المسافات بين حزم الألياف العضلية.

كما أظهرت نتائج الدراسة الحالية إنخفاضاً ملحوظاً لنشاط إنزيم السكسينيك ديهيدروجينز فى كل أنواع الألياف العضلية المأخوذة من حالات القدم القدفاء مشيرة إلى إنخفاض الطاقة الأيضية لتلك الألياف نتيجة للتغير التركيبى والوظيفى للسبقيات الموجودة بها .

وقد أظهر المجهر الإلكترونى تباعد الألياف العضلية المأخوذة من حالات القدم القدفاء عن بعضها وظهور مناطق تحلل وتبعثر لمكونات الألياف العضلية مع عدم إنتظام الفواصل بينها وأيضاً أظهرت سبقيات تلك الألياف العضلية عدم الانتظام فى الشكل والتوزيع. وكان هناك زيادة ملحوظة فى الألياف الضامة فيما بين الحزم العضلية. وكانت هذه الألياف العضلية المصابة محاطة بألياف أخرى سليمة.

وإحصائياً كان هناك زيادة معنوية فى نسبة الألياف العضلية من النوع (١) فى حالات القدم القدفاء بالمقارنة بالحالات الضابطة .

ويعتبر الخلل العضى الذى ظهر فى حالات القدم القدفاء خلل خلقى ناتج عن خلل عصبى عضلى وراثى ويمكن إعتبار اكتشاف وتحديد شدة التغيرات الهستوباثولوجية فى عضلات المواليد بحالات القدم القدفاء ذو أهمية فى تحديد نتيجة علاج هذه الحالات ومنع تكرار حدوثها بعد تعديلها جراحياً .

وَمَا يَكْفُرُ لَكَ بِهِ لَوْمَاتُ الْعَالِ  
لَا يَفْقَهُوا ظَنَّاكَ لَمَّاعًا يَا حَمِيمًا  
بَدَأَ خَلْقَ الْإِنسَانِ مِن طِينٍ  
مِمَّا يَخْتَلِفُ فِيهِ الْخَلْقُ أَجْمَعُ

وَاللَّهُ يَعْلَمُ أَسْرَارَ الْبَاطِنِ  
وَيَسْخَرُ لَكَ مَا تَشَاءُ مِنْ بَيْنِ يَدَيْهِ  
وَمَا خَلْفَ ظَهْرِكَ مِن دُونِ يَدَيْهِ  
وَمَا تَشَاءُ أُنزِلُكَ بِهِ سُلْطٰنًا  
مِّنَ السَّمَاءِ بِقُوتٍ مُّزِيدٍ

وَاللَّهُ يَخْتَارُ مَا يَسِّرُ وَيَصْعَقُ  
لَئِن يَشَاءُ اللَّهُ لَآتِيَنَّكُم بِقُوَّةٍ  
مِّنْ دُونِ الْبَحْرِ مِثْلَ طَرَفِ الْأَخْفَافِ  
وَلَوْ يَشَاءُ اللَّهُ لَآتَاكُم مِّنَ السَّمَاءِ  
مِثْلَ زُلْفَىٰ ذَرِيَّةً  
وَلَوْ يَشَاءُ اللَّهُ لَآتَاكُم مِّنَ السَّمَاءِ  
مِثْلَ سَدِاقِ الْبَدْرِ  
وَلَوْ يَشَاءُ اللَّهُ لَآتَاكُم مِّنَ السَّمَاءِ  
مِثْلَ سَدِاقِ الْبَدْرِ

وَاللَّهُ يَخْتَارُ مَا يَسِّرُ وَيَصْعَقُ  
لَئِن يَشَاءُ اللَّهُ لَآتِيَنَّكُم بِقُوَّةٍ  
مِّنْ دُونِ الْبَحْرِ مِثْلَ طَرَفِ الْأَخْفَافِ  
وَلَوْ يَشَاءُ اللَّهُ لَآتَاكُم مِّنَ السَّمَاءِ  
مِثْلَ زُلْفَىٰ ذَرِيَّةً  
وَلَوْ يَشَاءُ اللَّهُ لَآتَاكُم مِّنَ السَّمَاءِ  
مِثْلَ سَدِاقِ الْبَدْرِ  
وَلَوْ يَشَاءُ اللَّهُ لَآتَاكُم مِّنَ السَّمَاءِ  
مِثْلَ سَدِاقِ الْبَدْرِ

وَاللَّهُ يَخْتَارُ مَا يَسِّرُ وَيَصْعَقُ  
لَئِن يَشَاءُ اللَّهُ لَآتِيَنَّكُم بِقُوَّةٍ  
مِّنْ دُونِ الْبَحْرِ مِثْلَ طَرَفِ الْأَخْفَافِ  
وَلَوْ يَشَاءُ اللَّهُ لَآتَاكُم مِّنَ السَّمَاءِ  
مِثْلَ زُلْفَىٰ ذَرِيَّةً  
وَلَوْ يَشَاءُ اللَّهُ لَآتَاكُم مِّنَ السَّمَاءِ  
مِثْلَ سَدِاقِ الْبَدْرِ  
وَلَوْ يَشَاءُ اللَّهُ لَآتَاكُم مِّنَ السَّمَاءِ  
مِثْلَ سَدِاقِ الْبَدْرِ

وَاللَّهُ يَخْتَارُ مَا يَسِّرُ وَيَصْعَقُ  
لَئِن يَشَاءُ اللَّهُ لَآتِيَنَّكُم بِقُوَّةٍ  
مِّنْ دُونِ الْبَحْرِ مِثْلَ طَرَفِ الْأَخْفَافِ  
وَلَوْ يَشَاءُ اللَّهُ لَآتَاكُم مِّنَ السَّمَاءِ  
مِثْلَ زُلْفَىٰ ذَرِيَّةً  
وَلَوْ يَشَاءُ اللَّهُ لَآتَاكُم مِّنَ السَّمَاءِ  
مِثْلَ سَدِاقِ الْبَدْرِ  
وَلَوْ يَشَاءُ اللَّهُ لَآتَاكُم مِّنَ السَّمَاءِ  
مِثْلَ سَدِاقِ الْبَدْرِ

وَاللَّهُ يَخْتَارُ مَا يَسِّرُ وَيَصْعَقُ  
لَئِن يَشَاءُ اللَّهُ لَآتِيَنَّكُم بِقُوَّةٍ  
مِّنْ دُونِ الْبَحْرِ مِثْلَ طَرَفِ الْأَخْفَافِ  
وَلَوْ يَشَاءُ اللَّهُ لَآتَاكُم مِّنَ السَّمَاءِ  
مِثْلَ زُلْفَىٰ ذَرِيَّةً  
وَلَوْ يَشَاءُ اللَّهُ لَآتَاكُم مِّنَ السَّمَاءِ  
مِثْلَ سَدِاقِ الْبَدْرِ  
وَلَوْ يَشَاءُ اللَّهُ لَآتَاكُم مِّنَ السَّمَاءِ  
مِثْلَ سَدِاقِ الْبَدْرِ

وَاللَّهُ يَخْتَارُ مَا يَسِّرُ وَيَصْعَقُ  
لَئِن يَشَاءُ اللَّهُ لَآتِيَنَّكُم بِقُوَّةٍ  
مِّنْ دُونِ الْبَحْرِ مِثْلَ طَرَفِ الْأَخْفَافِ  
وَلَوْ يَشَاءُ اللَّهُ لَآتَاكُم مِّنَ السَّمَاءِ  
مِثْلَ زُلْفَىٰ ذَرِيَّةً  
وَلَوْ يَشَاءُ اللَّهُ لَآتَاكُم مِّنَ السَّمَاءِ  
مِثْلَ سَدِاقِ الْبَدْرِ  
وَلَوْ يَشَاءُ اللَّهُ لَآتَاكُم مِّنَ السَّمَاءِ  
مِثْلَ سَدِاقِ الْبَدْرِ