



SEPTAL DEFECT: WHAT ARE THE RISK FACTORS FOR ITS FAILURE? Running Title: Left Atrioventricular valve Function.

Mohamed-Adel Elgamel

Departments of Pediatric Cardiovascular Surgery and Pediatric Cardiology, Children's Hospital of Michigan, Detroit Medical Center,

Daniel Turner

Wayne State University, Detroit, Michigan.

Follow this and additional works at: <https://mmj.mans.edu.eg/home>

Recommended Citation

Elgamel, Mohamed-Adel and Turner, Daniel (2002) "SEPTAL DEFECT: WHAT ARE THE RISK FACTORS FOR ITS FAILURE? Running Title: Left Atrioventricular valve Function.," *Mansoura Medical Journal*: Vol. 31 : Iss. 2 , Article 2. Available at: <https://doi.org/10.21608/mjmu.2002.127094>

This Original Study is brought to you for free and open access by Mansoura Medical Journal. It has been accepted for inclusion in Mansoura Medical Journal by an authorized editor of Mansoura Medical Journal. For more information, please contact mmj@mans.edu.eg.

LONG-TERM FUNCTION OF THE LEFT ATRIOVENTRICULAR VALVE AFTER TWO-PATCH REPAIR OF COMPLETE ATRIOVENTRICULAR SEPTAL DEFECT: WHAT ARE THE RISK FACTORS FOR ITS FAILURE?

Running Title: Left Atrioventricular valve Function.

By

Mohamed-Adel F. Elgamal*, MD, Daniel Turner**, MD,

From

Departments of Pediatric Cardiovascular Surgery and Pediatric Cardiology**,
Children's Hospital of Michigan, Detroit Medical Center,
Wayne State University, Detroit, Michigan.*

ABSTRACT

Objective : To assess the function of the left atrioventricular valve (LAVV) following surgical repair of complete atrioventricular septal defect (CAVSD) and find out the possible risk factors for development of left atrioventricular valve regurgitation (LAVVR).

Methods : Over a ten-year period, 105 patients with the diagnosis of CAVSD underwent surgical repair using the two-patch technique at our institution. According to our inclusion criteria, only 97 patients were included in this study. Patients were evaluated preoperatively by full history taking, physical examination and 2-D

echo-Doppler evaluation. Intraoperative transesophageal echocardiography was performed in all patients.

Results : The included 51 boys and 46 girls. Age ranged from 70 to 517 days (mean of 182 ± 10.5). Body weight ranged from 3.8 to 8.2 Kg. (mean of 4.6 ± 0.15). Down's syndrome was present in 71 patients. Associated cardiac defects were present in 51 patients. Sixty-six patients had Rastelli type A, 6 had type B, and 25 had type C. The LAVV cleft was completely closed in 50, partially closed in 21 and left without closure in 26 patient. Additional annuloplasty was done in 13 patients. At discharge, the degree of LAVV

excluded; one hospital death, three late deaths and four lost from complete follow up. The remaining 97 patients constitute the patient population for this study. This series is limited to include only those with the complete form of the defect (i.e. common atrioventricular valve and a non-restrictive ventricular septal defect). Excluded from the study are patients with partial defect, transitional defect, those with associated tetralogy of Fallot, and the unbalanced forms of the defect for which the patient went on to single ventricle pathway. None of our patients had a previous pulmonary artery banding. Also, excluded from the study are patients who did not have intra-operative trans-esophageal echo-cardiography (TEE).

Preoperative evaluation included complete history taking and physical examination, full 2-D colored echo-Doppler study. Cardiac catheterization was done in 36 patients to evaluate the pulmonary vascular resistance. All patients had intraoperative, pre, and post-repair TEE study to evaluate the left atrioventricular valve (LAVV) function and assess the adequacy of the repair.

Operative Technique: All patients

were operated upon by the same surgical team. After aortic and direct bicaval cannulation, cardiopulmonary bypass was instituted and the heart was arrested using antegrade cold blood cardioplegia. Through a right atriotomy, the intracardiac anatomy was studied carefully to define the ventricular and the atrial components of the defect as well as the morphology and the pattern of chordal attachment of superior and the inferior bridging leaflets. The ventricular septum was examined for additional ventricular septal defects. Both ventricles were visually inspected to make sure that they are of adequate size. The right and the left ventricular outflow tracts were examined to rule out obstruction. The opposing points of the components of the mitral valve were determined by injection of cold saline into the ventricular cavity and were marked 6-0 prolene sutures. Detailed and unhurried assessment of these anatomical aspects has a positive impact on the surgical outcome, and also helps minimizing the risk of postoperative LAVVR. The ventricular component of the defect was closed using a glutaraldehyde-treated patch of autologous pericardium. This was sutured to the right side of the septum using 5-0 Tycron pled-

Postoperatively, patients were cared for in a pediatric cardiac intensive care unit. Before discharge, a pre-discharge full trans-thoracic 2-D colored echo-Doppler evaluation of the heart was obtained.

Postoperatively patients were followed up regularly at 6 to 12 months intervals at the outpatient clinic of the department of pediatric cardiology. At each visit, full history taking and complete medical examination of each patient was done. Echo-Doppler study was performed to evaluate the heart with special attention to the function of the LAVV. The Hospital files were obtained and preoperative, intraoperative and postoperative data were retrieved for analysis.

Statistical analysis : For statistical analysis the measured values were expressed as range (minimum, maximum), mean and the standard deviation of the mean (SD). Univariate analysis was used to identify the risk factor for failure of the LAVV. The possible risk factors studied included, age, gender, weight, Down's syndrome, preoperative pulmonary hypertension, associated cardiac defects, degree of pre-repair LAVV regurgitation, Rastelli type, cleft clo-

sure, and the degree of pre-discharge LAVV regurgitation. Freedom from re-intervention for LAVV regurgitation was analyzed using Kaplan-Meier curves and expressed with the 95% confidence limits.

RESULTS

Patient population: Ninety-seven patients were included in this study. Fifty-one were males (53%) and 46 were females (47%). Age ranged from 70 to 517 days (mean of 182 ± 10.5). Body weight ranged from 3.8 to 8.2 Kg. (mean of 4.6 ± 0.15).

Down's syndrome was present in 71 patients (73%). Associated cardiac defects were present in 51 patients (53%) {Table 1}.

Mean pulmonary vascular resistance in 36 patients who had cardiac catheterization was 6 ± 0.4 Woods units (range 2 to 11), which came down with hyperoxygenation to a mean of 2 ± 0.2 (range 0.5 to 6). As determined intraoperatively by the surgeon; 66 patients (68%) had Rastelli type A, 6 (6%) had type B, and 25 (26%) had type C. The intraoperative pre-repair degree of the LAVV regurgitation was none in 60 (62%), mild in 22 (23%), moderate in 11 (11%) and

Table 1: Associated cardiac defects in 51 patients.

Associated lesion	Number
Secundum ASD or PFO	15
PDA	20
Both ASD and PDA	14
Additional MVSD	2
Total	51(53%)

ASD = Atrial septal defect, PFO = Patent foramen ovale, PDA = Patent ductus

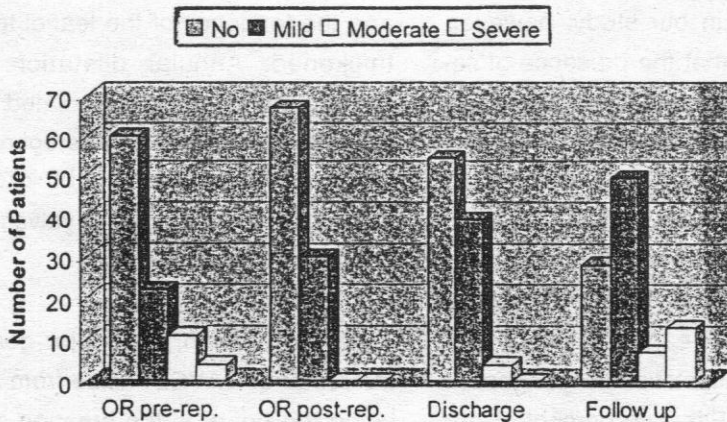


Figure 1 : Degree of the left atrioventricular valve regurgitation at various stages. OR pre-rep. = intraoperative pre-repair, OR post-rep. = intraoperative post-repair.

CAVSD in 1954 (17), a variety of surgical techniques have been used for repair of this anomaly with the major aim of improving late outcome in terms of LAVV function. The single patch technique, first introduced by Rastelli and associates at Mayo clinic, including violating the integrity of the bridging leaflets by dividing them, initially dominates (1, 18, 19). A gradual transition to the two-patch technique gradually happened since it was first introduced by Trusler in 1971(20) with the assumption that it has a superior results regarding the function of the LAVV as it does not violate the valve integrity and support the leaflets as it get sandwiched between the two patches creating an atrioventricular annulus for both the newly created left and right atrioventricular valves (2, 3, 5, 10). Others continued on using the single patch technique (7). Careful review of the reported results with both techniques fails to definitively document the superiority of one technique over the other. We have been using the two-patch technique and have no experience with the single-patch one. We also believe that the use of either technique is just a matter of the surgeon preference and experience. Recently there has been an interest in revival of the old technique of Lillehei

in repairing CAVSD with direct attachment of the common AVV to the crest of the ventricular septum without incorporating a patch. Two recent reports have shown good outcome in a small series (21, 22). Others have used an intermediate approach by using a smaller patch to close the ventricular septal component of the lesion (9). Because of the fact that an abnormal structural of the AVV is an integral component of this malformation, there is an inherent problem in retaining the competence of the valve even after complete repair (3).

Regardless to the technique used, the issue regarding the management of the cleft of the septal leaflet of the LAVV valve is not solved yet. Complete closure (the bifoliate approach), partial closure, and leaving the cleft opened (the trifoliate approach) have all been tried with variable conflicting results regarding the long-term function of the LAVV. Good results have been reported with bifoliate approach (7, 8, 10, 11, 16). On the other hand, trifoliate approach has been reported to have good long-term results. Authors who support this approach believe that it avoids aggressive manipulation of the LAVV. It also, according to their believes, preserve the

cant problem following successful surgical repair of CAVSD. The incidence has not improved, and better techniques to reduce or hopefully eliminate this problem are needed. It is an inherent problem to this unique cardiac defect regardless to the surgical approach used probably because of the congenitally deformed valve structure. We identified (so and so) as risk factors for reoperation for LAVVR. Based on our study we recommend repair of CAVSD at early age. We prefer the two-patch technique without division of the bridging leaflets. We also recommend complete closure (bicuspidization) of the LAVV cleft whenever possible unless LAVV stenosis is a real concern. Routine use of intraoperative TEE is very valuable in assessing the adequacy of the repair. Intraoperative post-repair LAVVR more than mild should not be accepted and is an indication to go back on pump for additional repair. Our experience, however, indicates that reoperation for late LAVVR can be done with low risk and excellent results. Most of these valves can be repaired. Valve replacement is rarely needed.

REFERENCES

- 1- Hanley FL, Fenton KN, Jonas RA, et al. (1993) : Surgical repair of complete atrioventricular canal defects in infancy: twenty-year trends. *J Thorac Cardiovasc Surg*; 106:387-97.
- 2- Alexi-Meskishvili V, Ishino K, Uhlemann F, Weng Y, Lange PE, Hetzer R. (1996) : Correction of complete atrioventricular septal defects with the double-patch technique and cleft closure. *Ann Thorac Surg*; 62:519-24.
- 3- Tewddell JS, Litwin SB, Berger S, et al. (1996) : Twenty-year experience with repair of complete atrioventricular septal defects. *Ann Thorac Surg*; 62:419-24.
- 4- Crawford FA Jr., Stroud MR. (2001) : Surgical repair of complete atrioventricular septal defect. *Ann Thorac Surg*; 72:1621-29.
- 5- Michielon G, Stellin G, Rizzoli G, Casarotto DC. (1997) : Repair of complete common atrioventricular canal defects in patients younger than four

- fect. *J Am Coll Cardiol*; 32:1449-53.
- 14- **Gunther T, Mazzitelli D, Haehnel CJ, Holper K, Sebening F, Meisner H. (1998)** : Long-term results after repair of complete atrioventricular septal defects: analysis of risk factors. *Ann Thorac Surg*; 65:754-60.
- 15- **McGrath LB, Gonzalez-Lavin L. (1987)** : Actuarial survival, freedom from reoperation, and other events after repair of atrioventricular septal defects. *J Thorac Cardiovasc Surg*; 94:582-90.
- 16- **Bonnetts PL, Goldberg SJ, Copeland JG. (1994)** : Frequency of left atrioventricular regurgitation postoperatively after repair of complete atrioventricular defect. *Am J Cardiol*; 74:1157-1160.
- 17- **Lillehei CW, Varco RL, Cohen M, Warden HE, Patton C, Moller JH. (1986)** : The first-open-heart repairs of ventricular septal defect, atrioventricular communis, and tetralogy of Fallot using extracorporeal circulation by cross-circulation: a 30-year follow-up. *Ann Thorac Surg*; 41:4-21.
- 18- **Rastelli GC, Ongley PA, Kirklin JW, McGoon DC. (1968)** : Surgical repair of complete form of persistent common atrioventricular canal. *J Thorac Cardiovasc Surg*; 55:299-308.
- 19- **Stuker M, Blackstone EH, Kirklin JW, et al. (1982)** : Determinants of early and late results of repair of atrioventricular septal (canal) defects. *J Thorac Cardiovasc Surg*; 84:523-42.
- 20- **Trusler GA. (1971)** : Correction of type C complete atrioventricular canal: Surgical considerations {discussion}. *J Thorac Cardiovasc Surg*; 71:72.
- 21- **Wilcox BR, Jones DR, Frantz EG, et al. (1997)** : anatomically sound, simplified approach to repair of