



---

## SUBCRANIAL TRANS-NASAL REPAIR OF CEREBROSPINAL FLUID RHINORRHEA WITH FREE AUTOLOGOUS GRAFTS BY THE COMBINED OVERLAY AND UNDERLAY TECHNIQUES

Omar El-Banhawy

*Department of ENT surgery, El Menoufyia University,*

Ahmed Halaka

*Department of ENT surgery, El Menoufyia University,*

Heshmat Ayad

*Department of ENT surgery, El Menoufyia University,*

Abdel-Hafiz Shehab El-Dien

*Departments of Neurosurgery at El-Hikmah Hospital&#039;; El- Mansoura International Hospital&quot;, Egypt.*

Follow this and additional works at: <https://mmj.mans.edu.eg/home>

---

### Recommended Citation

El-Banhawy, Omar; Halaka, Ahmed; Ayad, Heshmat; and Shehab El-Dien, Abdel-Hafiz (2003) "SUBCRANIAL TRANS-NASAL REPAIR OF CEREBROSPINAL FLUID RHINORRHEA WITH FREE AUTOLOGOUS GRAFTS BY THE COMBINED OVERLAY AND UNDERLAY TECHNIQUES," *Mansoura Medical Journal*: Vol. 32 : Iss. 2 , Article 12.

Available at: <https://doi.org/10.21608/mjmu.2003.127254>

This Original Study is brought to you for free and open access by Mansoura Medical Journal. It has been accepted for inclusion in Mansoura Medical Journal by an authorized editor of Mansoura Medical Journal. For more information, please contact [mmj@mans.edu.eg](mailto:mmj@mans.edu.eg).

# SUBCRANIAL TRANS-NASAL REPAIR OF CEREBROSPINAL FLUID RHINORRHEA WITH FREE AUTOLOGOUS GRAFTS BY THE COMBINED OVERLAY AND UNDERLAY TECHNIQUES

*By*

Omar A. El-Banhawy, Ahmed N. Halaka\*,  
Abdel-Hafiz Shehab El-Dien\*\*, Heshmat Ayad \*

*From*

*Department of ENT surgery, El Menoufyia University,*

*Departments of Neurosurgery at El-Hikmah Hospital \*,*

*El- Mansoura International Hospital\*\*, Egypt.*

## ABSTRACT

*Objective :* To determine the efficacy of subcranial trans-nasal repair of cerebrospinal fluid rhinorrhea with free autologous grafts by the combined overlay and underlay techniques using the surgical microscope and / or endoscope.

*Patients and Methods :* Twenty patients with CSF rhinorrhea were included in this retrospective study. They were 13 males and 7 females. Their age ranged from 7 to 62 years (mean 39.35). The etiologies of the leak were iatrogenic in 10 cases, spontaneous in 5 cases, traumatic in 4 cases and one case was associated with meningeo-encephalocele. Preop-

erative nasal endoscopic examination, computed tomography (CT) with intrathecal non-ionic contrast and magnetic resonance image (MRI) were done when indicated. Endoscopic and / or microscopic repair of CSF fistula was done by a combination of both under lay and overlay repair with free autologous grafts as follows: Gelfoam with fibrin glue, strips of fat, fascia lata, Gelfoam with fibrin glue (underlay), septal cartilage, Gelfoam with fibrin glue and strips of fat (overlay).

*Results :* Complete closure of the leak was achieved in all patients. In one case of spontaneous CSF leak which was operated endoscopically,

the leak was recurred 6 months postoperatively and ceased spontaneously after a month with conservative medical treatment. No major complications were seen and no patients developed meningitis or postoperative anosmia.

**Conclusion:** Subcranial transnasal repair with free autologous grafts by the combined overlay and underlay techniques using endoscope or surgical microscope is a safe successful method of treating CSF leaks, provided that the CSF leak is precisely located and the site can be reached by an endoscope or surgical microscope.

*Key words :* Cerebrospinal Fluid rhinorrhea, subcranial, transnasal, endoscopic, microscopic.

## INTRODUCTION

Cerebrospinal fluid (CSF) rhinorrhea involves a breakdown of all barriers that separate the subarachnoid space from the upper aerodigestive tract, namely, the mucosa of the nasal cavity or paranasal sinus, skull base (i.e., bone), dura mater, and arachnoid membrane. It was first described in the second century AD by Galen [1].

The surgical management of a CSF fistula remains controversial as it depends on the etiology of the leak, the location of the fistula and the temporal relationship of the leak to inciting factor [2]. An open craniotomy procedure has consistently been the neurosurgical procedure of choice. Some authors reported excellent results 90 % [3], whilst other groups had seen lower success rates of approximately 60 % [4].

In recent years, the microscopic and endoscopic repair of CSF fistula have gained popularity and are now considered by most to be the treatment of choice for CSF rhinorrhea repair [1-2]. Despite the popularity gained by these approaches, the literatures reported a wide range of grafting materials used to repair the leaks, including autologous materials (such as abdominal fat, septal mucosa, turbinate bone, temporalis fascia and fascia lata); homologous materials (such as cadaveric pericardium and fascia lata) and allografts (such as hydroxyapatite cement) [5-6-7-8-9].

These materials may be used as underlay (i.e. between the dura and skull base) or overlay (i.e., over the nasal site of the defect). Controversy

also exists regarding the need for "fixators" such as packing and/or fibrin glue [5-6-7-8-9].

### THE AIM OF THE WORK

The aim of this study was to determine the efficacy of subcranial transnasal repair of cerebrospinal fluid rhinorrhea with free autologous grafts by the combined overlay and underlay techniques using endoscopes or surgical microscope.

### PATIENTS AND METHODS

This study was conducted between August 1995 and August 2000. Twenty patients with CSF rhinorrhea were managed at El-Hikma Hospital for Neurosurgery and El-Mansoura International Hospital, Dakahlia, Egypt.

The patients' age ranged from 7 to 62 years (average 39.35). They were 13 males and 7 females. The etiologies of the leaks were iatrogenic in 10 cases, spontaneous (normal pressure leak) in 5 cases, traumatic in 4 cases and one case was associated with meningo-encephalocele.

#### *Patients with iatrogenic CSF rhinorrhea*

They were 10 cases. Four were

peroperative during sublabial-transseptal-trans-sphenoid hypophysectomies, 2 were peroperative during functional endoscopic sinus surgery (FESS) for chronic ethmoidal sinusitis, 2 during FESS for sinonasal polyposis, one case was during excision of stage IIIb juvenile angiofibroma (based on Fisch classification, Andrews et al.[10], Fig.1) by endoscopic-assisted midfacial degloving approach (Table: 1). The last case developed CSF leak 8 days postoperatively after sublabial-transseptal-trans-sphenoid hypophysectomy. The CSF leak was from the sella floor CT cisternogram and MRI.

#### *Patients with spontaneous (normal pressure leak) CSF rhinorrhea*

They were 5 cases. They were presented with symptoms of spontaneous intermittent unilateral CSF rhinorrhea which failed to respond to conservative medical treatments. The leak was persisted for a period ranged from 5-10 months. Preoperative CT cisternogram and MRI showed evidence of the leak in all cases (Fig. 2& 3).

#### *Patients with traumatic CSF rhinorrhea*

They were 4 cases. CSF leaks

were due to minor head injury, and the fracture lines were at the floor of the anterior cranial fossa as demonstrated by high-resolution computed tomography and MRI. None of these patients required other operative intervention.

*Patient with meningo-encephalocele*

He was 20 years old. Intermittent CSF rhinorrhea with unilateral nasal obstruction due to intranasal cavity mass was the presenting symptoms. CT and MRI showed the evidence of the lesion (Fig. 4).

None of the patients in this study had meningitis or previously undergone neurosurgical craniotomy.

Preoperative nasal endoscopic examination was done to all patients with spontaneous, traumatic, meningo-encephalocele and to the patient who developed CSF leak after sublabial-transseptal-trans-sphenoid hypophysectomy to diagnose and localize the clear fluid emanating from the middle meatus, superior meatus, or the sphenoethmoid recess indicated the site of leakage to be from the roof of the anterior ethmoid sinus, the posterior ethmoid sinus, or the sphenoid sinus. CSF was collected and ana-

lyzed to confirm its nature by its specific gravity, protein level, chloride, and glucose level.

Preoperative high resolution plane CT, CT with intrathecal non ionic contrast (cisternogram) in axial and coronal cuts and MRI for the brain and paranasal sinuses using 2 mm slices thickness were done for patients with spontaneous, traumatic CSF rhinorrhea, meningo-encephalocele, and to case who developed CSF leak after sublabial-transseptal-trans-sphenoid hypophysectomy to show any causative intracranial lesions, to identify bony abnormalities within the sinuses or skull base, to determine the site and size of the defect.

All patients had preoperative and postoperative antibiotic cover. Lumbar CSF drainage was not necessary.

Transnasal endoscopic repair of CSF fistula was done for cases with spontaneous leak (5 cases), traumatic (4 cases), iatrogenic peroperative during FESS for chronic ethmoidal sinusitis (2 cases), peroperative FESS for sinonasal polyposis (2 cases), excision of stage IIIb nasopharyngeal angiofibroma with intracranial extension and excision of menin-

geo-encephalocele. The last case was excised and repaired as prescribed by Mattox and Kennedy [11].

Fistulae occurred peroperatively during sublabial-transseptal- transphenoid hypophysectomy or postoperatively were repaired utilizing the same approach with the surgical microscope.

The repair was carried out as follows: Once the defect was identified, the surrounding bony edges and mucosa around the defect were freed from soft tissues for an area of 2 to 3 mm with small-cupped forceps in order to allow the graft to firmly adhere to the skull base. The fistula was repaired by placing the grafting material as follows: Gelfoam with fibrin glue (rapid polymerizing fibrin glue was prepared from autologous blood as described by Stechison[12], strips of fat harvested from the thigh during obtaining facia lata, free autogenous facia lata graft, Gelfoam with fibrin glue (the underlay graft), adequate size piece of septal cartilage (obtained by septoplasty), Gelfoam with fibrin glue, strips of fat (overlay graft, Fig. 5). Under this lied a layer of packing ribbon gauze soaked in Gentamycin cream and which was stayed

in place for 3 days.

Patients were reviewed weekly as outpatients and performed sterile saline nasal douches until the Gelfoam had desorbed (3 to 5 weeks). Patient's follow-up ranged from 7 to 52 months (average 25.95).

## RESULTS

The most common causes of CSF rhinorrhea in this work were predominantly iatrogenic (10 cases, 50 %) and spontaneous (5 cases 25 %, Table 1).

Preoperative radiological evaluations (plane CT, CT cisternogram and MRI) showed the exact locations and sizes of the leaks (defects) in all patients (Table 1). MRI showed the bright signal from trapped CSF or herniated arachnoid in the dural-bone defect and T2 weighted images showed the same finding as CT cisternogram as regard the site and size of CSF fistulae (Fig.2).

The size of the bone defects was varied from 3 to 18 mm (Tables 1 & 2). The most common site of leakage was the ethmoidal roof/ cribriform plate (Table 1). Four cases with spontaneous CSF rhinorrhea were

due to cribriform plate defects and one case was due to defect in roof of the sphenoid (Fig. 2 & 3). The defects in cribriform plate were mainly in fovea ethmoidalis adjacent to anterior ethmoidal artery.

There were no major operative or postoperative complications. Postoperative intranasal synechia were found in 3 patients in the first 2 weeks

of surgery. They were divided under local anesthesia.

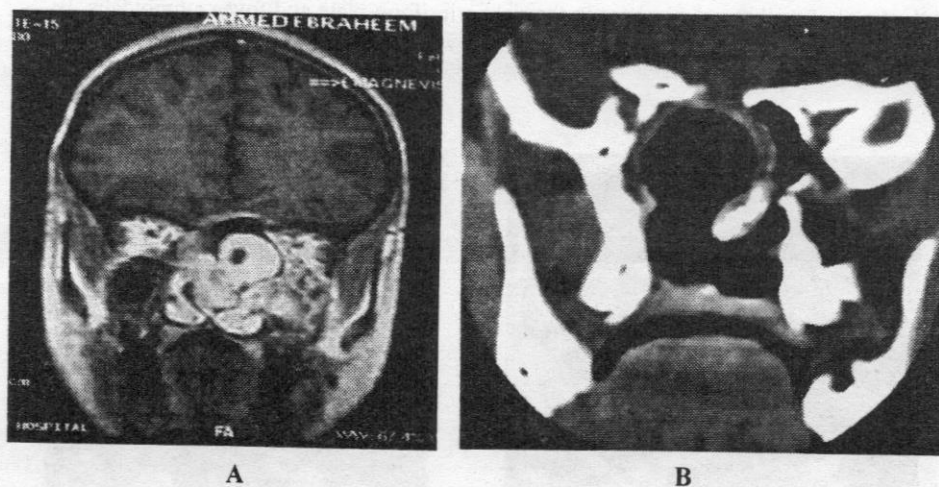
Complete closure of the leaks was achieved in all patients. In one case of spontaneous CSF leak that was operated endoscopically, the leak recurred 6 months postoperatively and ceased spontaneously after a month with conservative medical treatment.

Table 1: The age, sex, etiology, size, site, follow-up period and outcome for the patients treated surgically for CSF Rhinorrhea.

No	Age	Sex	Etiology	Size In mm	Site	Follow-up period in months
1	35	M	Trauma	3	R anterior fovea ethmoidalis post. to AEA	13
2	48	F	Spontaneous leak	5	R anterior fovea ethmoidalis adjacent to AEA	7
3	51	M	During sublabial-transseptal-trans-sphenoid hypophysectomy	10	Roof of the sphenoid	48
4	49	F	Spontaneous leak	8	Left posterior ethmoid at junction between superior turbinate and fovea ethmoidalis	10
5	20	M	During FESS for chronic ethmoidal sinusitis	3	At junction between superior turbinate and fovea ethmoidalis	8
6	62	M	Trauma	4	Left lateral wall of the olfactory fossa	18
7	35	M	During FESS for chronic ethmoidal sinusitis	8	At the attachment of middle turbinate to fovea ethmoidalis	20
8	20	M	meningo-encephalocele	15	Anterior fovea ethmoidalis post. To AEA	22
9	29	M	Trauma	4	Right lateral wall of the olfactory fossa	22
10	46	F	Eight days after sublabial-transseptal-trans-sphenoid hypophysectomy	18	Roof of the sphenoid	32
11	30	F	Spontaneous leak	7	Left anterior fovea ethmoidalis adjacent To AEA	26
12	47	M	During FESS for sinonasal polyposis	9	At junction between middle turbinate and fovea ethmoidalis	48
13	41	F	During sublabial-transseptal-trans-sphenoid hypophysectomy	17	Roof of the sphenoid	52
14	55	M	Spontaneous leak	6	R anterior fovea ethmoidalis post. to AEA	10
15	29	M	Trauma	4	Right lateral wall of the olfactory fossa	48
16	52	M	FESS for sinonasal polyposis	8	Roof of the sphenoid	24
17	53	M	During sublabial-transseptal-trans-sphenoid hypophysectomy	16	Roof of the sphenoid	56
18	11	M	During excision of stage IIIb nasopharyngeal angiofibroma by endoscopic-assisted midfacial degloving approach	13	Left posterior ethmoid at junction between superior turbinate and fovea ethmoidalis	38
19	49	F	During sublabial-transseptal-trans-sphenoid hypophysectomy	15	Roof of the sphenoid	7
20	38	F	Spontaneous leak	8	Roof of the sphenoid	10

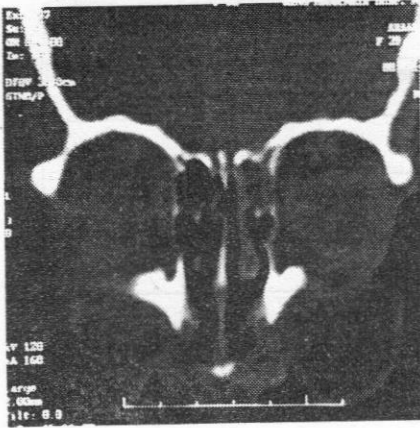
Table 2: Size of the bone defects in the patients treated surgically for CSF Rhinorrhea.

Size in mm	Number of patients	%
From 3-6	7	35%
From 7-10	7	35%
From 11-14	1	5%
From 15-18	5	25%

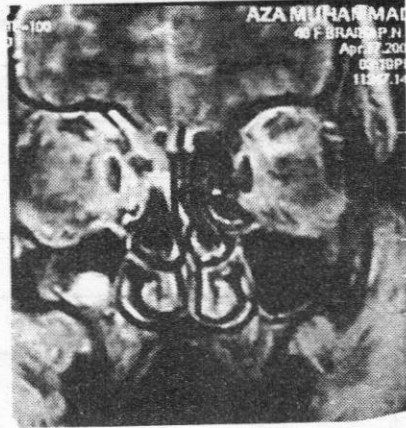

**Fig. 1: A Patient with iatrogenic CSF rhinorrhea:** Preoperative MRI for type IIIb nasopharyngeal angiofibroma invading the infratemporal fossa, orbital region with intracranial extradural parasellar involvement who had endoscopic-assisted midfacial degloving approach with transnasal endoscopic repair for iatrogenic CSF rhinorrhea occurred during tumor removal from fovea ethmoidales region. **Fig B:** Coronal CT with contrast two years postoperatively of the same patient showing complete clearance of the tumor and intact skull base.



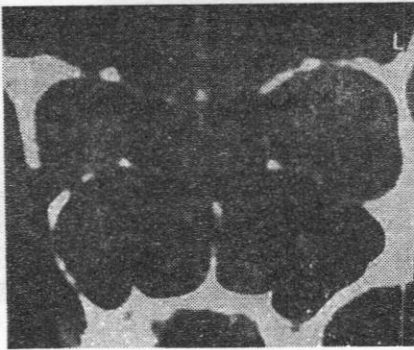

A

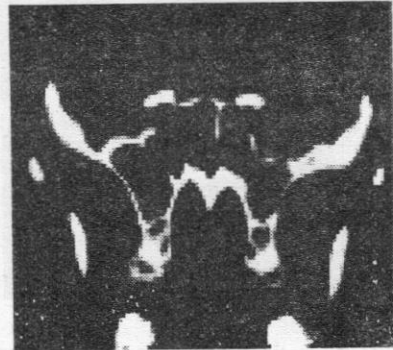


B

**Fig. 2 :** A case of spontaneous CSF: A- CT cisternogram showing contrast accumulation at the level of the bony dehiscence in the right cribriform plate and fovea ethmoidalis. B: MRI for the same patient showing accumulation at the same site.

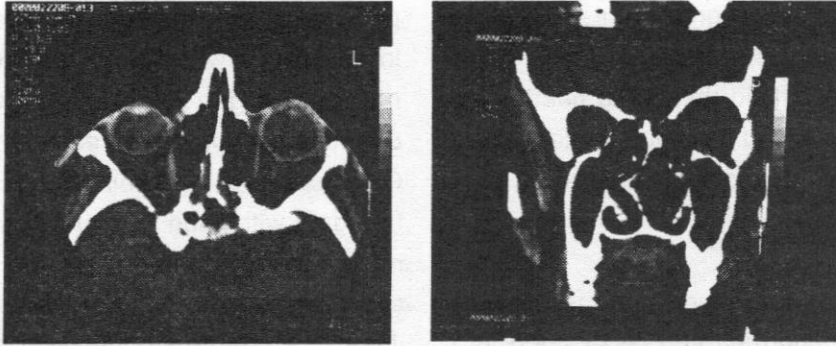


A

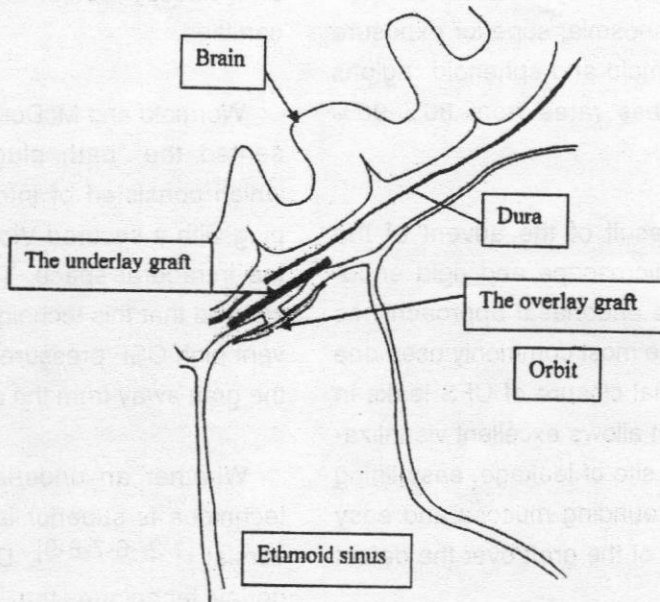


B

**Fig. 3: A:** case of spontaneous CSF: CT cisternogram showing contrast accumulation at the level of the bony dehiscence in the left cribriform plate and fovea ethmoidalis. **B:** Another case of spontaneous CSF: Plain CT scan showing opacification of the sphenoid sinus due to trapped CSF with bony dehiscence at the roof of the sphenoid sinus.



**Fig. 4 :** The patient with meningo-encephalocele: Plain axial and coronal CT showing herniated intranasal meningo-encephalocele between nasal septum and cribriform plate.



**Fig. 5 :** Illustration showing the schematic drawing of the overlay and underlay technique used to repair cerebrospinal fluid fistula in the current work.

## DISCUSSION

Galen first described CSF rhinorrhea in the second century AD. Since that time, the management of cerebrospinal fluid rhinorrhea has historically plagued the neurosurgeons and the otolaryngologist-head and neck surgeons [1-13].

The operative management of CSF rhinorrhea can be divided into intracranial and extracranial approaches; each has its advantages and disadvantages [3-14]. Extracranial repairs are associated with decreased morbidity, decreased incidence of anosmia, superior exposure of the ethmoid and sphenoid regions with success rates from 80%-90% [14].

As a result of the advent of the surgical microscope and rigid endoscope, the endonasal approach has become the most commonly used one for the initial closure of CSF leaks in this area. It allows excellent visualization of the site of leakage, easy lifting of the surrounding mucosa and easy placement of the graft over the defect [7].

Throughout the literatures, the choice of materials used during micro-

scopic or endoscopic repair of CSF fistulas seems to depend on the experience and familiarity of the operating surgeons with the various techniques. Wigand [5], and then Stankeiwicz [6], described repairing CSF fistulas using turbinate mucosa free graft with fibrin glue and postauricular fat and temporalis fascia, respectively. Papay et al. [15] described the endoscopic repair of spontaneous or traumatic CSF rhinorrhea using fascia lata, muscle, and fat. Lanza et al. [7], repaired 42 skull base defects in 36 patients using mucoperichondrial and mucoperiosteal graft and septal cartilage.

Wormald and McDonough [16] presented the "bath plug" technique, which consisted of introducing a fat plug with a secured Vicryl suture into the intradural space. These authors claimed that this technique would prevent high CSF pressure from pushing the graft away from the defect.

Whether an underlay or overlay technique is superior is also controversial [1-2--6-7-8-9]. During an underlay technique, the intact dura is detached from the edge of the bony defect to expose an adequate buttress for stable graft insertion. The

graft is designed in such a way that it can be pushed a few millimeters between the bone and the raised intact dura on all sides of the defect. The overlay (onlay) technique was used if there was a risk that nerves or vessels might be damaged when raising the dura from the surrounding bone or when inserting the graft, or if an inlay technique was not technically possible. The graft was placed over the dural lesion and over exposed bony margins that had been denuded. The graft is then supported in place with layers of some type of fixator, such as Gelfoam, Surgicel, or fibrin glue [8-17].

The combined overlay and underlay technique used in this work was designed to prevent CSF pressure from pushing the graft away from the defect. The facia lata is strong grafting material, easy to obtain in adequate size with fat from the thigh and was easy to design in such a way to be pushed few millimeters between the bone and the raised intact dura on all sides of the defect. Gelfoam with fibrin glue were used to fix the graft in place. Septal cartilage was used to provide rigid support for the graft in place and to be in continuation with the surrounding anterior skull bone.

The graft is held in place with strips of fat to obtain a tight seal, easy to be vascularised and it will act as over lay (onlay) graft.

Fibrin glues have been widely used in neurosurgery [18]. These glues are mainly said for prevention of cerebrospinal fluid (CSF) leakage but are also used for achieving hemostasis on the dura mater, for cranioplasty using resected autologous bone fragments, for anastomoses of nerves and vessels, and for the inclusion of antibiotics [12-18]. In the current work Fibrin glue was used as a sealant rather than as an adhesive and also to form a tough fibrin clot plate that sufficiently seals dural tears to prevent (CSF) leakage. It was used as an adjunct and not a substitute for a watertight closure that provides the most assured means of avoiding CSF leak.

In the present study among 15 cases of CSF rhinorrhea who underwent endoscopic repair of CSF fistulas, there was a case that had recurrence of CSF rhinorrhea after 6 months. This patient did not like to have any more surgical intervention for this leak. During his follow-up the CSF rhinorrhea eased eventually in

one month with conservative therapy.

Failure of repairing the defect by the endoscopic approach may be related to inability to successfully localize the defect, graft displacement, insufficient graft size, incomplete apposition of the graft to the skull base defect, and patient non-compliance with post-operative instructions [9].

There have been 2 large studies that have examined the success of endoscopic repair of CSF fistulas for all etiologies [19-7]. Dodson et al. [19], treated 29 cases of CSF rhinorrhea with endoscopic techniques. Seventy-five percent had resolution after their initial repair. Duration of follow-up ranged from 3 to 43 months. Lanza et al. [7], reviewed 36 patients that underwent endoscopic repair of CSF fistulas. During the first attempt, successful endoscopic repair was achieved in 94%.

#### *Conclusion*

Subcranial transnasal repair with free autogenous grafts by the combined overlay and underlay techniques appears to be a safe method of treating CSF leaks with low morbidity, provided that the site of the CSF leak is precisely located. The parallel

development of new techniques of radiological and endoscopic imaging and instrumentation seems to meet these requirements.

## REFERENCES

- 1- **Hegazy HM, Carrau RL, Snyderman CH, Kassam A, Zweig J. (2000)** : Transnasal endoscopic repair of cerebrospinal fluid rhinorrhea: a meta-analysis. *Laryngoscope*, Jul; 110(7):1166-72.
- 2- **Nachtigal D, Frenkiel S, Yoskovitch A, Mohr G. (1999)** : Endoscopic repair of cerebrospinal fluid rhinorrhea: is it the treatment of choice? *J Otolaryngol*, Jun; 28(3):129-33.
- 3- **Costa H, Cerejo A, Baptista A, Vaz R, Goncalves M, Guimaraes A, Amarante J, Cruz C, Guimaraes F. (1993)** : The galea frontalis myofascial flap in anterior fossa CSF leaks. *Br J Plast Surg*. Sep; 46(6):503-7.
- 4- **Park JI, Strelzow VV, Friedman WH. (1983)** : Current management of cerebrospinal

- fluid rhinorrhea. Laryngoscope. Oct; 93(10):1294-300.
- 5- **Wigand WE. (1981)** : Transnasal ethmoidectomy under endoscopic control. Rhinology, 19:7-15.
- 6- **Stankiewicz JA. (1991)** : Cerebrospinal fluid fistula and endoscopic sinus surgery. Laryngoscope, Mar; 101(3):250-6.
- 7- **Lanza DC, O'Brien DA, Kennedy DW. (1996)** : Endoscopic repair of cerebrospinal fluid fistulae and encephaloceles. Laryngoscope, Sep; 106(9 Pt 1):1119-25.
- 8- **Burns JA, Dodson EE, and Gross CW. (1996)** : Transnasal endoscopic repair of cranionasal fistulae: a refined technique with long-term follow-up. Laryngoscope, Sep; 106(9 Pt 1):1080-3.
- 9- **Van Den Abbeele T, Elmaleh M, Herman P, Francois M, Narcy P. (1999)** : Transnasal endoscopic repair of congenital defects of the skull base in children. Arch Otolaryngol Head Neck Surg., May; 125(5):580-4.
- 10- **Andrews JC, Fisch U, Valavanis A, Aeppli U, Makek MS. (1989)** : The surgical management of extensive nasopharyngeal angiofibromas with the infratemporal fossa approach. Laryngoscope, Apr; 99(4): 429-37.
- 11- **Mattox DE, Kennedy DW. (1990)** : Endoscopic management of cerebrospinal fluid leaks and cephaloceles. Laryngoscope, Aug; 100(8):857-62.
- 12- **Stechison MT (1992)** : Rapid polymerizing fibrin glue from autologous or single donor blood: Preparation and indications. J Neurosurg 76:6 26D628.
- 13- **Applebaum EL & Chow J.M. (1999)** : Otolaryngology head and neck surgery (volume 2-A) 3rd edition,. Charles W.Cummings, John M. Fredrickson, Lee A.

Harker and others editors.  
Mosby, London.

**14- Daly DT, Lydiatt WM, Ogren FP, Moore GF. (1992) :** Extra-cranial approaches to the repair of cerebrospinal fluid rhinorrhea. *Ear Nose Throat J.*, Jul; 71(7):311-3.

**15- Papay FA, Maggiano H, Dominquez S, Hassenbusch SJ, Levine HL, Laveru P. (1989) :** Rigid endoscopic repair of paranasal sinus cerebrospinal fluid fistulas. *Laryngoscope* Nov; 99(11):1195-201.

**16- Wormald PJ, McDonogh M. (1997) :** 'Bath-plug' technique for the endoscopic management of cerebrospinal fluid leaks. *J Laryngol Otol.*, Nov; 111(11):1042-6.

**17- Weber R, Keerl R, Draf W,**

**Schick B, Mosler P, Saha A. (1996) :** Management of dural lesions occurring during endonasal sinus surgery. *Arch Otolaryngol Head Neck Surg.*, Jul; 122(7):732-6.

**18- Van Velthoven V, Clarici G, Auer LM (1991) :** Fibrin tissue adhesive sealant for the prevention of CSF leakage following transsphenoidal microsurgery. *Acta Neurochir (Wien)* 109:26D29.

**19- Dodson EE, Gross CW, Swerdloff JL, Gustafson LM. (1994) :** Transnasal endoscopic repair of cerebrospinal fluid rhinorrhea and skull base defects: a review of twenty-nine cases. *Otolaryngol Head Neck Surg.* Nov; 111(5):600-5.