



ENDOSCOPIC ENDONASAL PARTIAL MIDDLE TURBINECTOMY APPROACH: ADAPTABILITY OF THE PROCEDURE IN A CADAVERIC STUDY AND IN SURGERY FOR DIFFERENT SPHENOID SINUS AND SKULL BASE LESIONS

Omar El-Banhawy

Department of ENT surgery, ElMenoufyia University, Departments of Neurosurgery at El- Mansoura International Hospital

Abdel-Hafiz Shehab El-Dien

Department of ENT surgery, ElMenoufyia University, Departments of Neurosurgery at El- Mansoura International Hospital

Ahmed Zolfakar

Department of Anatomy El Menoufyia University

Ahmed Halaka

Departments of Neurosurgery at El- Mansoura International Hospital

Heshmat Ayad

Departments of Neurosurgery at El-Hikmah Hospital, Egypt

Follow this and additional works at: <https://mmj.mans.edu.eg/home>

Recommended Citation

El-Banhawy, Omar; Shehab El-Dien, Abdel-Hafiz; Zolfakar, Ahmed; Halaka, Ahmed; and Ayad, Heshmat (2003) "ENDOSCOPIC ENDONASAL PARTIAL MIDDLE TURBINECTOMY APPROACH: ADAPTABILITY OF THE PROCEDURE IN A CADAVERIC STUDY AND IN SURGERY FOR DIFFERENT SPHENOID SINUS AND SKULL BASE LESIONS," *Mansoura Medical Journal*: Vol. 32 : Iss. 2 , Article 13.
Available at: <https://doi.org/10.21608/mjmu.2003.127255>

This Original Study is brought to you for free and open access by Mansoura Medical Journal. It has been accepted for inclusion in Mansoura Medical Journal by an authorized editor of Mansoura Medical Journal. For more information, please contact mmj@mans.edu.eg.

ENDOSCOPIC ENDONASAL PARTIAL MIDDLE TURBINECTOMY APPROACH: ADAPTABILITY OF THE PROCEDURE IN A CADAVERIC STUDY AND IN SURGERY FOR DIFFERENT SPHENOID SINUS AND SKULL BASE LESIONS

By

Omar A. El-Banhawy, Abdel-Hafiz Shehab El-Dien*,
Ahmed S. Zolfakar**, Ahmed N. Halaka***, Heshmat Ayad.***

From

Department of ENT surgery, El Menoufyia University, Departments of Neurosurgery at El- Mansoura International Hospital, Department of Anatomy El Menoufyia University**, Departments of Neurosurgery at El-Hikmah Hospital ***, Egypt.*

ABSTRACT

Objective : To demonstrate the flexibility, adaptability and efficacy of endoscopic endonasal removal of inferior half of the middle turbinate in a cadaveric study and in surgery for the treatment of different sphenoid sinus and skull base lesions.

Study Design : prospective study

Methods : *Anatomic Cadaveric*

Study : Five adult cadaveric heads were studied. Six nostrils of 3 cadavers were studied endoscopically after removal of lower half of the middle turbinate. Two adult cadaveric heads underwent bilateral paraseptal sagittal sections and studied after removal of the lower half of the middle turbinate.

Surgical study : Sixty five patients with different sphenoid sinus and skull base related lesions underwent surgery through this approach.

Results :

In anatomic cadaveric study : This approach offered more surgical space, less restricted tubular vision and offered wider anatomic panoramic orientation with 0° and angled endoscopes.

In the surgical group : there was no major intra- or postoperative complications. The approach allowed better exposure, accessibility of the lesion and subsequently good hemostasis, tumor resection and re-

pair of the skull base defect.

Conclusion : The current approach provided wider surgical field without leading to more morbidity. It avoids unnecessary trauma of the other nostril as in binostril approach. The harvested piece of turbinate tissue obtained is an excellent source of donor material for successful reconstruction of the sellar floor without inducing side effects or complications.

Key words : middle turbinate; endoscopic, endonasal.

INTRODUCTION

During the past decade, the endoscopic endonasal approach for the treatment of different sphenoid sinus and related skull base lesions has increased in popularity as it improved patient comfort due to its minimal invasiveness [1-2]. The procedure offered a panoramic view, allowing observation of all anatomic structures along the surgical route, as well as those located in skull base [2].

Cappabianca et al. [3] addressed three "problems" with the endoscopic endonasal approach: (1) less room to work, (2) conflicts between the surgeon's hands and the instruments, and (3) possible damage to intranasal

structures during the introduction of instruments into the nose.

The middle turbinate is of a significant importance as a landmark of the lateral nasal wall in endoscopic endonasal surgery [4]. The removal of the lower half of the middle turbinate did not affect, to a great extent, its physiological function and stability [5].

To determine the efficacy of excision of the lower half of the middle turbinectomy in endoscopic endonasal surgery for the treatment of different sphenoid sinus and skull base lesions, a preliminary endonasal endoscopic anatomic study with excision of the lower half of the middle turbinate in cadavers has been carried out. Subsequently, partial inferior middle turbinectomy became a standard step in our endoscopic endonasal surgery for the treatment of different sphenoid sinus and skull base lesions.

RELEVANT ANATOMY

Middle turbinate Surgical Anatomy:

The middle turbinate is a part of the ethmoid bone covered by mucus membrane with ciliated columnar epithelium and overhangs the middle meatus (Fig.1: A). It lies medial to

several important sinus structures. These include the anterior ethmoid air cells, the maxillary sinus ostium, the nasofrontal duct, and the uncinat process. The mean length of the middle turbinate is 40 mm and its mean height is 14.5 mm anteriorly and 7 mm posteriorly [6]. The anterior end of the middle turbinate has its line of attachment running almost vertically upward to join the remainder of the turbinate at the angle of the genu. Beneath this genu lies the frontal recess. The anterior third of the middle turbinate inserts to the base of the skull at the lateral edge of the cribriform plate (lamina cribrosa). The middle third of the middle turbinate is fixed to the lamina papyracea by its ground lamella, which runs in an almost frontal plane. The posterior third of the middle turbinate (horizontal ground lamella) is attached to the lamina papyracea and / or the lateral wall of the nasal cavity [6].

There are some anatomical variations of the middle turbinate which include L shaped middle turbinate, paradoxically bent middle turbinate, a concha bullosa, and a sagittal groove formation of the inferior aspect of the middle turbinate. Hyper pneumatization of the middle

turbinate is known as concha bullosa, it usually occurs bilaterally. It can produce a significant obstruction of the middle meatus, the hiatus semilunaris and the ethmoid infundibulum. In such cases, surgical treatment (partial resection of the concha bullosa) may be considered [5].

The following points should be remembered in endoscopic nasal surgery :

- 1) The vertical anterior portion of the middle turbinate is attached to the cribriform plate, hence, medial displacement of the middle turbinate, when necessary should be done with extreme care so as not to fracture its superior attachment.
- 2) The middle turbinate converges toward the superior turbinate posteriorly and its posterior end becomes an important landmark when the sphenoid ostium in the sphenoidal recess is searched for endoscopically.
- 3) The main sphenoid sinus cavity is usually located above and medially to the posterior attachment of the middle turbinate.
- 4) During endoscopic nasal surgery, it is important to recognize the superior attachment of the middle turbinate to avoid an injury to the cribriform plate [6].

MATERIAL & METHODS

Anatomic Cadaveric Study :

Five adult cadaveric heads were studied. All utilized cadaver specimens had well pneumatized sphenoid sinuses. Six nostrils of 3 cadavers were studied endoscopically. Endoscopic removals of lower half of the middle turbinate for these cadavers were carried out followed by an endoscopic anatomical examination.

Since nasal endoscopy usually carried out by introducing the endoscope between the nasal turbinates and nasal septum, bilateral parasagittal sections of the other 2 adult cadaveric heads were made between the nasal septum and the middle turbinate toward the rostrum of the sphenoidal sinus (Fig. 1). The approach was studied after removal of lower half of the middle turbinate.

Rigid endoscopes, 4 mm in diameter and 18-cm in length, with 0°, 30°, and 70° lenses were used. Integrated imaging system with high resolution digital still camera and a three-chip digitally enhanced video camera enabled still and video images of the endoscopic anatomy to be captured during the study. Digital pictures were reproduced by coupling the

video images with a computer video capture system.

Surgical study group :

Between June 1997 and December 2002, sixty five consecutive patients with different sphenoid sinus and skull base related lesions underwent endoscopic endonasal surgery with lower half middle turbinectomy approach. They were managed at ENT and Neurosurgery departments in El-Menoufyia University Hospital, El-Menoufyia, El-Hikma Hospital for Neurosurgery and El-Mansoura International Hospital, Dakahlia, Egypt. All patients had clinical assessments including preoperative nasal endoscopy prior to surgery. Ophthalmic, endocrine and radiological evaluations (plain x-ray, plain CT scans, CT cisternogram, MRI and MRI with contrast) were done when indicated prior to surgery.

Patients with pituitary adenomas

The group consisted of 45 patients 25 males and 20 females between 20 and 67 years of age. The histological diagnoses of pituitary adenomas were microadenomas in 20 patients; intrasellar macroadenomas in 21; and 4 had macroadenomas with suprasellar extension. Four patients

had recurrent pituitary adenomas. Hormone-secreting pituitary adenomas were found in 21 patients (18 with prolactinomas and 3 were acromegalic). Twenty four patients had nonsecreting pituitary adenomas (21 patients presented with a visual disorder and 3 with symptoms of pituitary apoplexy). Patients with prolactinomas had received bromocriptine therapy previously with little improvement.

Patients with isolated sphenoid sinus inflammatory disease

The group consisted of 10 patients, 6 male and 4 female, between 28 and 75 years of age. All patients showed evidence of isolated sphenoid sinus inflammatory disease, which did not resolve by medical treatment. Surgical findings of these cases were inspissated secretions (7 patients), fungal debris (2 patients), and mucopyoceles (1 patient).

Patients with meningoencephalocele

The group consisted of 3 patients 2 males and one female, between 8 and 34 years of age. Spontaneous intermittent CSF rhinorrhea and/or nasal obstruction due to intranasal cavity mass were the presenting

symptoms in all patients. CT scans and MRI showed the lesions in all cases.

Patients with CSF rhinorrhea from Sphenoid sinus

They were 3 male patients. A 65 - year-old man with headache and intermittent binostril rhinorrhea for 6 months after the 5th functional endoscopic sinus surgery for recurrent sinonasal polyposis involving the sphenoid sinus. CT cisternogram scan and MRI showed evidence of CSF leak inside the sphenoid sinus associated with nasal polyposis. The second patient was 45 -year-old man who had parasellar pituitary macroadenoma removed through sublabial transnasal transseptal transsphenoidal microsurgical approach followed by radiotherapy at age of 32 years. He developed intermittent bilateral CSF rhinorrhea at 6 months prior to surgery. CT cisternogram and MRI showed evidence of CSF leak inside the left sphenoid sinus compartment with large intrasellar arachnoid cyst. The third patient was 35 years who developed spontaneous intermittent unilateral rhinorrhea for 5 months. CT cisternogram and MRI revealed a cranial base defect in the floor of the sella turcica.

Patients with clivus chordoma

The group consisted of 2 male patients aged 34 and 48 years. Headache was the presenting symptom in the first case and headache with diplopia due to oculomotor and abducent nerves palsy were the presenting symptoms in the second one. CT scans and MRI showed the clivus chordoma lesions in the 2 cases.

Patients with skull base meningiomas

They were 2 male patients aged 40 and 45 years old. The first case was an extensive greater wing meningioma reaching the nasal cavity. It was treated by combined approach (trans-cranial pterional approach for the cranial part and the current approach for the trans-nasal part). Surgery was followed by radiotherapy to the residual tumor in the lateral sellar compartment. The second case was recurrent olfactory groove meningioma which was treated also by combined approach (oblique subfrontal approach for the cranial part and the current approach for the trans-nasal part).

Surgical technique :

The procedure is performed by otolaryngologist or by a team surgery

by both an otolaryngologist and a neurosurgeon. The operation was performed under hypotensive general anesthesia. The nose is packed with 1:100,000 of epinephrine cottonoids. The patient lied in a reversed Trendelenburg position with approximately 20° above the horizontal with the head tilted to the right, extended approximately 10° and secured with Mayfield head pins.

The entire procedure was approached via a nostril. The C-arm was brought in and positioned in a way that a cross-table lateral radiogram could be performed for the sphenoid sinus and sella. The face and right lower quadrant of the abdomen were sterilely prepared and draped. Prophylactic antibiotics were administered. A septoplasty was performed to correct markedly deviated septum in 10 cases. Septoplasty incision was on the contralateral side of the approached nostril. Initially, a 0° endoscope was used. The middle turbinate was injected with 1% lidocaine with 1:100,000 of epinephrine and the lower half was excised (Fig. 2: A&B). The bleeding from the inferior surface of the remaining part of the middle turbinate was controlled by bipolar diathermy. The upper half was not

violated as it is directly attached to anterior skull base and to avoid a CSF leak [5]. Because of the lower half of middle turbinate had been removed the full length of ipsilateral nasal cavity including the related part of anterior skull base was widened and exposed.

The procedure was followed according the nature of the lesions. Patients with pituitary adenomas were dealt with by the methods prescribed by Jho et al. [7]. Isolated sphenoid sinus inflammatory diseases were dealt with according to the method prescribed by Stammberger et al [8]. Patients with meningo-encephalocele and CSF rhinorrhea were dealt with according to the method prescribed by Mattox and Kennedy [9]. Chordoma and meningioma were dealt with by the methods prescribed by Jho et al. [10-11].

In cases that required reconstruction of the skull base defect, the harvested turbinate tissue was used to repair the defect in a manner where the turbinate bone and mucoperiosteum will lay superiorly toward the surgical site of the lesion and the covering turbinate mucosa will lay inferiorly toward nasal cavity.

At the end of the procedure, bilateral anterior nasal packs with vaseline-impregnated gauze and gentamycin ointment were inserted into the nasal cavities. Patients were kept in the hospital to apply systemic intravenous antibiotic, to observe them for the onset of diabetes insipidus, removal of the nasal pack, after 48 hours of surgery, to exclude CSF leak or other complications. Patient follow-up ranged from 7 to 48 months

RESULTS

Anatomic Cadaveric Study :

The presence of the nasal septum medially and middle turbinates laterally made the field of vision is restricted by the size and shape the middle. Removal of the inferior half of the middle turbinate offered more surgical space, less restricted tubular vision and avoided, to a great extent, coaxial work of the micro instruments inside the nasal cavity (Fig. 1:B).

Removal of the lower half of the middle turbinate exposed the full length of the ipsilateral anterior wall of the sphenoid sinus which facilitated identification of the ipsilateral natural opening of the sinus and removal of its anterior wall (Fig. 1: B).

The approach offered wider anatomic panoramic orientation, with 0° and 30° endoscopes, of the surgical field in the ipsilateral nasal cavity, and sphenoid sinus related structure. The 0° endoscopes provided the least distortion in the surgical anatomical images. The angled endoscopes with 30° and 70° lenses provided an extended lateral view that clarified remote anatomic corners (Fig. 1: C). They also enhanced distortion of the same anatomic structures.

Surgical study group :

Patients with pituitary adenomas

There was neither neural nor vascular injury. Intraoperative CSF leak was encountered in 14 patients (12 macroadenomas and 2 microadenomas). The mean operative time was 2.1 hours (standard deviation: 0.7) and the average intraoperative blood loss was 130-ml. No postoperative CSF leaks or other complications that could be related to the partial middle turbinectomy or the closure technique occurred in this series.

Temporary diabetes insipidus (DI) occurred in 3 cases. Hospital stays was overnight in 21 patients, 2-nights in 18 patients, 3 nights in 6 patients. Postoperative intranasal synechia

were found in 5 patients in the first 2 weeks of surgery. They were divided under local anesthesia. For patients with prolactinomas: 14 patients were cured clinically and endocrinologically and 4 improved clinically with mildly elevated serum prolactin levels and "bromocriptine therapy" was applied. Acromegalic patients were cured clinically and hormonologically. In cases with nonsecreting pituitary macroadenomas who presented with a visual disorder, exhibited improvement of their visual acuity and visual fields. Patients with symptoms of pituitary apoplexy experienced resolution of their symptoms following surgery.

Patients with isolated sphenoid sinus inflammatory disease

There were no major operative or postoperative complications. Partial middle turbinectomy facilitated the approach (Fig. 3: A&B), as well as postoperative cleaning and surveillance. All patients were symptom free by 12 weeks postoperatively and have remained so during the follow-up period (mean follow-up, 23.1 months).

Patients with meningo-encephalocele

It was originating from the ethmoid complex in 2 patients (Fig. 4: A,B&C)

and from the junction between nasal septum and cribriform plate in the third one. Complete excision of the herniated part and closure of the defect were achieved in all patients. No complications were seen and no patients developed meningitis or postoperative anosmia.

Patients with CSF rhinorrhea from Sphenoid sinus

The defects were in sellar floor. The sizes of the defects were 2 millimeter in 2 cases and 4 in the third one (patient with intrasellar arachnoid cyst, Fig. 5: A,B,C and D). There were no major operative or postoperative complications and complete closure of the leak achieved in all patients with no recurrence during the follow up period.

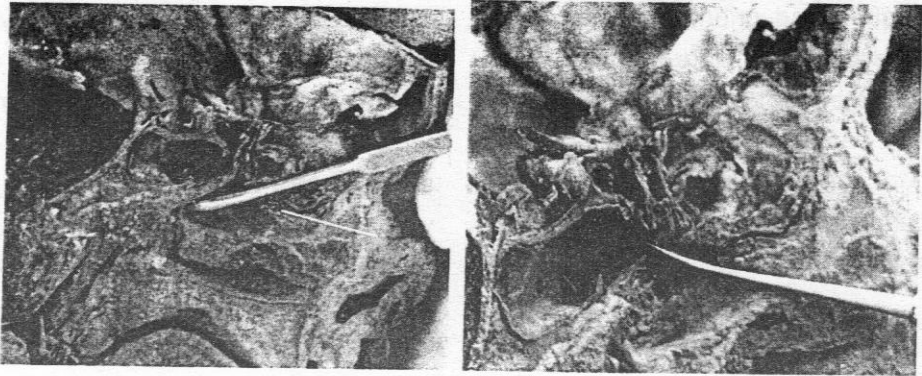
Patients with clivus Chordoma

There was no major intra or postoperative complication (e.g. CSF leake or cranial nerves paralysis). Subtotal resection (at least 90% of tu-

mor removed, as estimated by postoperative MRI 6 months after surgery) was achieved in one case (Fig. 6: A). A partial resection (less than 90% of tumor removed as estimated by postoperative MRI 6 months after surgery) was noted in the second 3 months after surgery. This patient had endoscopically assisted transoral-transpharyngeal approach to the craniovertebral junction prescribed by Frempong-Boadu et al. [12].

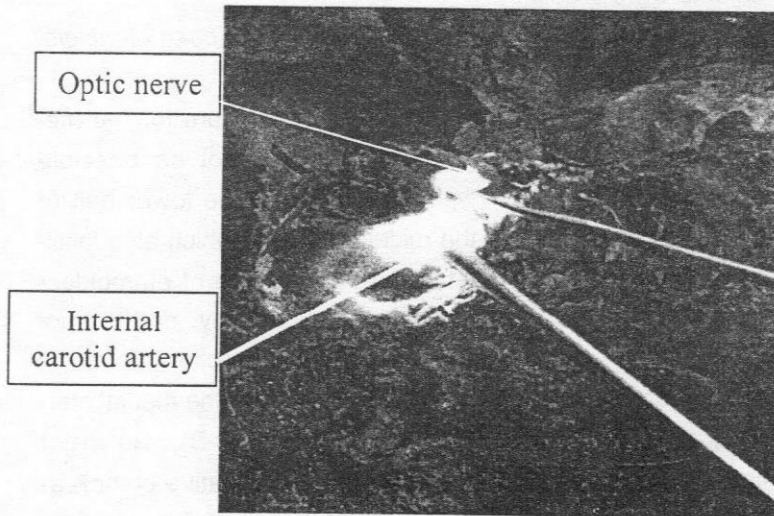
Patients with skull base Meningiomas

Endoscopic exposure for the meningiomas would not be possible without excision of the lower half of the middle turbinate which also facilitated the performance of ethmoidectomy, sphenoidectomy, good tumor visualization and resection around of the palatine bone and the medial pterygoid process (Fig. 6: B). No major operative or postoperative complications were seen and skull reconstruction was successful with no CSF leak.



A

B



C

Fig. 1 A : sagittal view of cadaver specimen at the level of attachment of left middle turbinate to anterior skull base and lateral wall of the nose and the yellow line is at the site of desirable incision. Freer elevator placed at the anterior wall of the sphenoid sinus. **B:** the same view after removal of the lower half of the middle turbinate and a nterior sphenoidotomy. **C:** the same view with 30° endoscope introduced to view the upper part of sellar compartment.

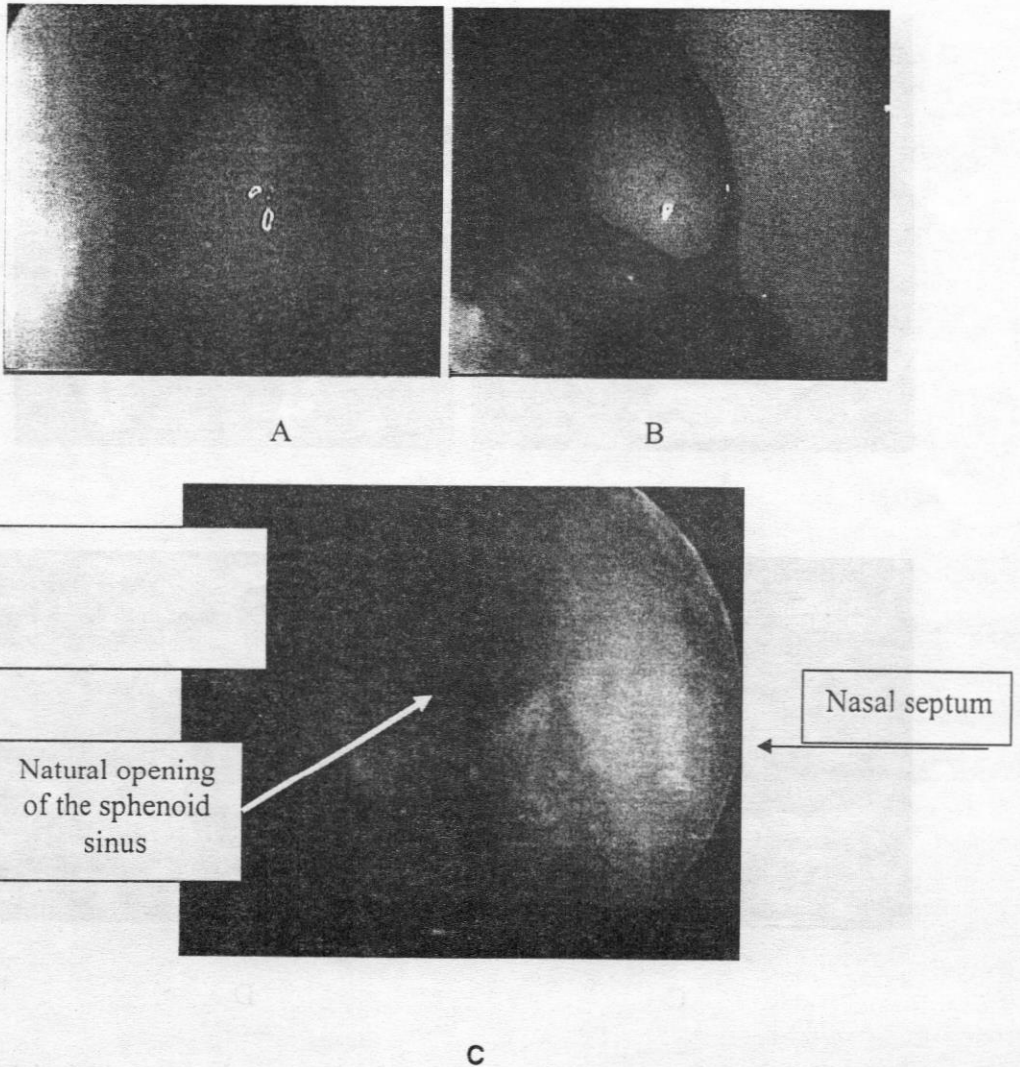


Fig. 2. A : endoscopic view (0)⁰ of the left nasal cavity showing the attachment of left middle turbinate to anterior skull base and lateral wall of the nose. **B:** the same view showing the site of removal of the lower half of the left middle turbinate. **C:** A surgical field obtained after excision of the lower half of the right middle turbinate.

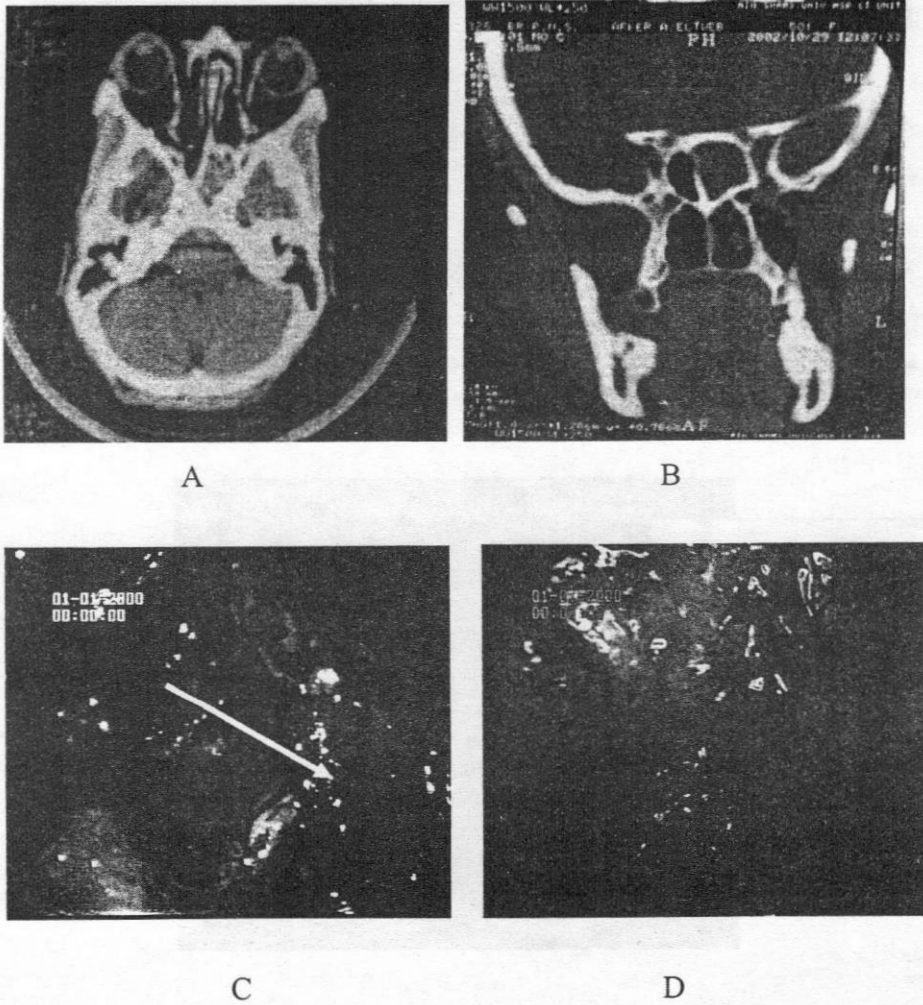
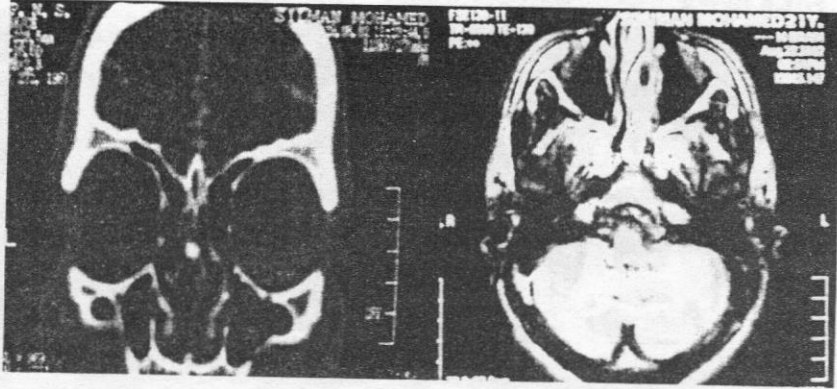
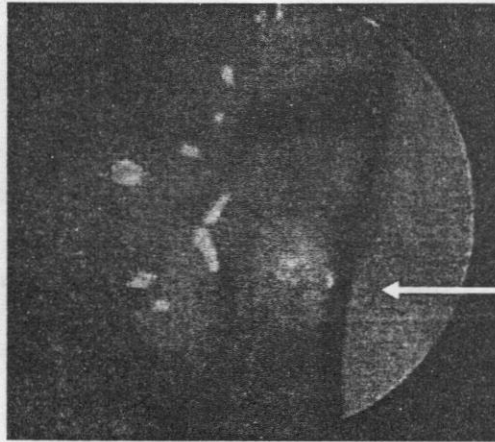


Fig. 3. A : Preoperative plain CT (axial and coronal views) of a case with isolated sphenoid fungal sinusitis. **B:** Intraoperative endoscopic (30°) view of the same case showing the fungal debris filling the lower compartment of the sphenoid sinus (arrow). **C:** The same endoscopic view after removal of the fungal debris and appearance of the inferior compartment of the sphenoid sinus.



A

B



C

Fig. 4. A : Preoperative plain CT (coronal view) showing herniated intranasal meningo-encephalocele in the left nasal cavity (arrow). **B:** Preoperative non contrast MRI (axial T2 WI) of the same case. **C:** Intraoperative endoscopic (30°) view of the same case showing the meningo-encephalocele protruding between left middle turbinate and lateral nasal wall.

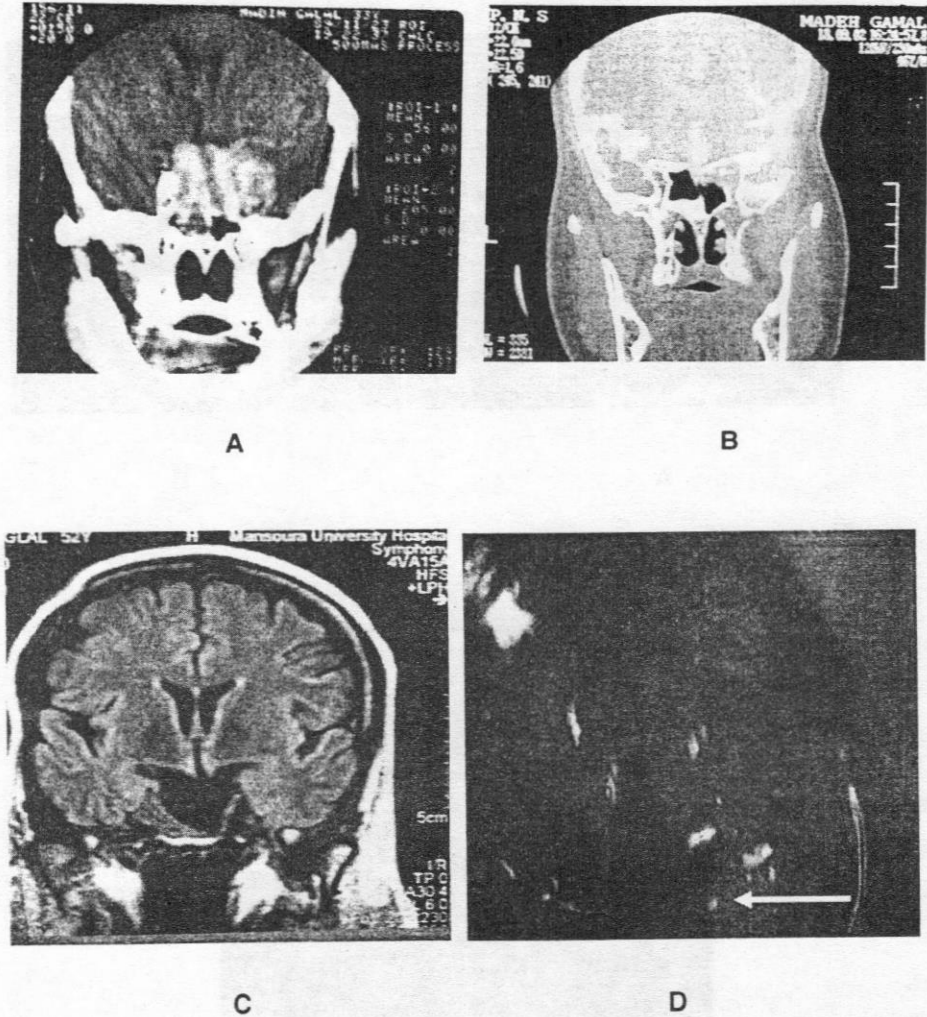


Fig. 5. A : Preoperative plain CT (coronal view) of a case of sellar and parasellar pituitary macroadenoma. **B:** Postoperative plain CT (coronal view) of the same case when presented by delayed CSF rhinorrhea 12 years after surgical removal of the lesion via sublaminar microsurgical approach and followed by postoperative radiation. **C:** Preoperative non contrast MRI (coronal T2 WI) of the same lesion showing large CSF collection mostly arachnoid pouch filling most of the sellar cavity. **D:** Intraoperative endoscopic (30°) view of the same case showing internal carotid artery protruded through the medial wall of right cavernous sinus (arrow).

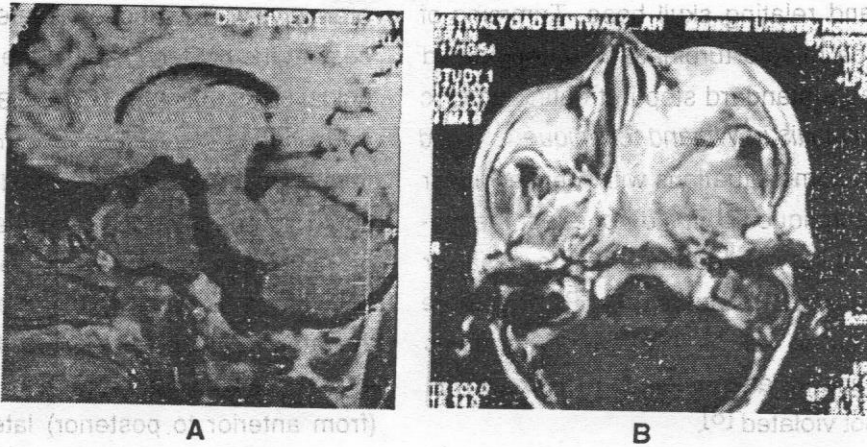


Fig. 6. A : Preoperative non contrast MRI (axial T1 WI) of a 48 years old male with the clivus chordoma lesion. Partial resection was achieved (less than 90% of tumor removed) was noted in the second 3 months after surgery. This patient had endoscopically assisted transoral-transpharyngeal approach to the craniovertebral junction prescribed by Frempong-Boadu et al. [19]. **B:** Preoperative non contrast MRI (axial T2 WI) of the case with the extensive greater wing meningioma reaching the nasal cavity. It was treated by combined approach (transcranial pterional approach for the cranial part and endonasal endoscopic with lower half middle turbinectomy for the trans-nasal part) and followed by radiotherapy.

Discussion

In 1987, Griffith & Veerapen [13] introduced a direct endonasal endoscopic approach to the pituitary, and since then, several endonasal endoscopic techniques have been reported for the treatment of different sphenoid sinus and related skull base lesions. Increasing experience and gaining confidence with this approach, allowed different modifications aimed to tailor the technique for individual

nasal, paranasal sinuses and related skull base lesions.

Endoscopic endonasal anatomic features could be distorted because of deviation of the nasal septum, hypertrophy of both turbinates, concha bullosa of the middle turbinates, and/or other unexpected anatomic variations. These variations can produce difficulties and reduced safety in accessing the nasal cavity

and relating skull base. Trimming of the middle turbinate was considered as a standard step in treating chronic sinusitis in Wigand technique [14] and in some situations with Messerklinger technique [5]. It did not affect the mucociliary's clearance of the nasal or paranasal sinus cavity [5] and there was no risk of CSF leak as far as its superior attachment to skull base was not violated [8].

In the anatomic cadaveric study of this work with removal of the lower half of the middle turbinate, the endonasal use of the 0° and angled endoscopes provided an extended ipsilateral view of the full length of the nasal cavity. Using 0° endoscope the entire anterior wall of the sphenoid sinus could be visualized (fig.3 B) which facilitated anterior sphenoidotomy. When the angle of the 30° endoscope directed medially it provided extended ipsilateral view of the mucoperichondrium covering the nasal septum and related cribriform plate and when directed laterally the entire lateral wall of the nose was visualized (Fig. 2:C).

Through an anterior sphenoidotomy with the use of a 0° endoscope the posterior wall of the sphenoidal sinus was visualized with a wide pan-

oramic view. To expose the lateral recess at the posterior wall of the sphenoidal sinus, 30° and 70° angled-lens endoscopes were used. Rostral extension of the anterior sphenoidotomy could be adjusted to reach the area of planum sphenoidale superiorly, floor of the sphenoid sinus inferiorly, the lateral wall of the nasal cavity and lateral wall of the sphenoid sinus (from anterior to posterior) laterally, the entire length of the nasal septum and rest of the sphenoid cavity medially.

In surgery for pituitary adenomas of the current work, a 0° endoscopes provided a wider exposure and the ipsilateral paramedian compartment of the posterior wall of the sphenoid sinus was at the center of the surgical exposure. Once the sella was entered and dura mater was diathermized and opened the tumor was removed under direct endoscopic visualization, while preserving the normal pituitary gland tissue. The wider surgical field created by this approach enhanced visualization of the suprasellar region, especially with the 30° endoscope (Fig. 4: D). The previously harvested piece of turbinate tissue obtained by the current approach was utilized in repairing the sellar floor defect so there was no

need to use any other reconstructive materials either autogenous materials like cartilaginous or bony septum, which in some occasions they were unavailable [7] or artificial foreign materials like titanium plates [15] or ceramic substances [16]. These materials are limited by their rigidity, availability, compatibility with magnetic resonance imaging and its cost. Using the current approach for pituitary surgery the operating time and intraoperative bleeding were less than that reported in the literatures [2-7].

Endoscopic endonasal approaches to the sphenoid sinus inflammatory diseases can be done through the nasal side or from posterior ethmoid cells [8-14-18]. The last approach is longer, difficult, and involving unnecessary surgery in cases with isolated sphenoid sinus inflammatory disease [18]. Endoscopic endonasal approach to the sphenoid sinus can be done through the rostrum of the sphenoid or through the natural os [17] which could be difficult because of the variable anatomy or due to presence polypoid disease. The current the approach provided less crowding of instruments in the working nostril and allowed more bulky instruments to be used (e.g. a sidebiting rongeur and an

antral backbiting rongeur). Anterior sphenoidotomy through the rostrum of the sphenoid or through the natural os became easier, safer and quicker. It also facilitated postoperative cleaning of the surgical field so avoided the risk of sphenoid sinus opening stenosis or reinfection which were reported by others [18].

In cases with clivus chordoma, the approach created a wider hollow surgical space large enough to expose the clival region. The optics and illumination of the endoscope were in the field of the resection at the level of the abnormality which allowed safer extensive resection of the lesion. By rotation of 30° angled endoscope, we were able to look laterally and inferiorly to obtain a larger panoramic view allowing maximum clearance of the lesion. The current technique reduces the overall morbidity associated with other approaches [10-19].

Wide exposure of the meningeoencephalocele and meticulous hemostasis are essential for surgical success [9]. In the present work, adequate access of herniated part of the lesion was facilitated by removal of lower half of the middle turbinate which allowed easy manipulation of

the bipolar coagulation forceps for good hemostasis and gradual fulguration of the lesion to avoid intracranial hemorrhage. As a sequence of better accessibility by the current approach the, the 0° or 30° endoscopes were used to expose the skull base for several millimeters around the defect allowing the harvested piece of turbinate tissue to reconstruct the defects with other grafting material (e.g. Gelfoam). The maneuver was easy to perform and a watertight seal was achieved without restriction related to the working space if compared to other similar approaches [9-20].

Kato et al. [21], described difficulties encountered during endonasal resection of anterior skull base lesions including meningiomas. These difficulties were in part associated with restrictions imposed by the deep narrow working channel intrinsic to this approach and significant limitations to the exposure of tumors with lateral extensions making control of the source of hemorrhage due to lateral position of the offending vessel extremely difficult. With the middle turbinate approach, the anterior sphenoidotomy can be extended laterally to the pterygoid bone, thus allowing wider access to the lateral sphenoidal

sinus structures. This allowed better exposure of the intranasal part of the meningiomas and subsequently good hemostasis and tumor resection.

CONCLUSION

The current approach provided wider surgical field without leading to more morbidity. It avoids unnecessary trauma of the other nostril as in binasal approach. The harvested piece of turbinate tissue obtained is an excellent source of donor material for successful reconstruction of the sellar floor without inducing side effects or complications.

REFERENCES

- 1- **Gibbons MD, Sillers MJ. (2002) :** Minimally invasive approaches to the sphenoid sinus. *Otolaryngol Head Neck Surg Jun; 126(6):635-41*
- 2- **Nasseri SS, Kasperbauer JL, Strome SE, McCaffrey TV, Atkinson JL, Meyer FB. (2001) :** Endoscopic transnasal pituitary surgery : report on 180 cases. *Am J Rhinol. Jul-Aug; 15(4) : 281-7.*
- 3- **Cappabianca P, Alfieri A, de Divi-**

- tiis E. (1998) : Endoscopic endonasal transsphenoidal approach to the sella: towards functional endoscopic pituitary surgery (FEPS). *Minim Invasive Neurosurg.* Jun; 41(2):66-73.
- 4- Becker SP (1994) : Applied anatomy of the paranasal sinuses with emphasis on endoscopic surgery, *Ann Otol Rhinol Laryngol Suppl* 162:3.
- 5- Liu Z, Wang C, Gao Q, Cui Y. (2002) : The effect of managements of middle turbinate on nasal airway resistance in endoscopic sinus surgery. *Lin Chuang Er Bi Yan Hou Ke Za Zhi* May; 16(5):201
- 6- Yanagisawa E. (1993) : Endoscopic view of the middle turbinate. *Ear Nose Throat J.* Nov; 72(11): 725-7.
- 7- Jho HD, Carrau RL, Ko Y (1996) : Endoscopic pituitary surgery, in Rengachary SS, Wilkins RH (eds): *Neurosurgical Operative Atlas.* Park Ridge, Ill: American Association of Neurological Surgeons, Vol 5, pp 1-12
- 8- Stammberger H (1986) : Endoscopic endonasal surgery-- concepts in treatment of recurring rhinosinusitis. Part II. Surgical technique. *Otolaryngol Head Neck Surg* 94:147-156.
- 9- Mattox DE, Kennedy DW. (1990) : Endoscopic management of cerebrospinal fluid leaks and cephalocele. *Laryngoscope.* Aug; 100(8):857-62.
- 10- Jho HD, Ricardo L. Carrau, Mark L. McLaughlin, and Salvador C. (1996) : Soma-za Endoscopic transsphenoidal resection of a large chordoma in the posterior fossa. Case report. *Neurosurgical Focus*, July, Volume 1, Number 1.
- 11- Jho HD (2001) : Endoscopic transsphenoidal surgery. *J Neurooncol Sep*; 54(2):187-95.
- 12- Frempong-Boadu AK, Faunce WA, Fessler RG. (2002) :

- Endoscopically assisted transoral - transpharyngeal approach to the craniovertebral junction. *Neurosurgery*. Nov; 51(5 Suppl):60-6.
- 13- Griffith HB, Veerapen R (1987) : A direct transnasal approach to the sphenoid sinus [technical note]. *J Neurosurg*, 66:140-142.
- 14- Wigand M (1990) : Endoscopic surgery of the paranasal sinuses and anterior skull base. New York, Thieme.
- 15- Arita K, Kurisu K, Tominaga A, Ikawa F, Iida K, Hama S, Watanabe H. (1999) : Size-adjustable titanium plate for reconstruction of the sella turcica: Technical note. *J Neurosurg*. 91:1055-1057.
- 16- Kobayashi S, Sugita K, Matsuo K, Inoue T (1981) : Reconstruction of the sellar floor during transsphenoidal operations using alumina ceramic. *Surg Neurol*. 15:196-197.
- 17- Alieri A. (1999) : Endoscopic endonasal transsphenoidal approach to the sellar region: technical evolution of the methodology and refinement of a dedicated instrumentation. *J Neurosurg Sci*. Jun; 43(2):85-92.
- 18- Martin TJ, Smith TL, Smith MM, Loehrl TA. (2002) : Evaluation and surgical management of isolated sphenoid sinus disease. *Arch Otolaryngol Head Neck Surg*. Dec; 128(12):1413-9.
- 19- Gay E, Sekhar LN, Rubinstein E, Wright DC, Sen C, Jannecka IP, Snyderman CH. (1995) : Chordomas and chondrosarcomas of the cranial base: results and follow-up of 60 patients. *Neurosurgery*. May; 36 (5) : 887-96.
- 20- Marshall AH, Jones NS, Robertson IJ. (2001) : Endoscopic management of basal encephaloceles. *J Laryngol Otol*. Jul; 115(7):545-7.
- 21- Kato T, Sawamura Y, Abe H, Nagashima M (1998) : Transsphenoidal transtuberulum sellae approach for supradiaphragmatic tumours: Technical note. *Acta Neurochir (Wien)* 140:715-719.