



LOCALIZATION OF NEURONAL NITRIC OXIDE SYNTHASE IN THE SPINAL CORD OF POSTNATAL ALBINO RAT: A HISTOCHEMICAL STUDY.

Mona El-Shahat

Department of Anatomy, Faculty of Medicine, Mansoura University.

Follow this and additional works at: <https://mmj.mans.edu.eg/home>

Recommended Citation

El-Shahat, Mona (2004) "LOCALIZATION OF NEURONAL NITRIC OXIDE SYNTHASE IN THE SPINAL CORD OF POSTNATAL ALBINO RAT: A HISTOCHEMICAL STUDY.," *Mansoura Medical Journal*: Vol. 33 : Iss. 1 , Article 1. Available at: <https://doi.org/10.21608/mjmu.2004.127426>

This Original Study is brought to you for free and open access by Mansoura Medical Journal. It has been accepted for inclusion in Mansoura Medical Journal by an authorized editor of Mansoura Medical Journal. For more information, please contact mmj@mans.edu.eg.

LOCALIZATION OF NEURONAL NITRIC OXIDE SYNTHASE IN THE SPINAL CORD OF POSTNATAL ALBINO RAT : A HISTOCHEMICAL STUDY.

By
Mona A. El-Shahat

From

Department of Anatomy, Faculty of Medicine, Mansoura University,

ABSTRACT

The postnatal developmental changes in the localization of nitric oxide synthase were studied in the spinal cord of albino rats using nicotinamide adenine dinucleotide phosphate-diaphorase (NADPH-d) histochemistry. At birth, NADPH-d positive neurons were present in the pericentral zone, the intermediolateral cell column and the deep dorsal horn (laminae IV-V). Moderately positive neurons were scattered in the ventral horn. NADPH-d positive nerve fibers were seen crossing to the opposite side in the pericentral zone, extending between the pericentral zone and thoracolumbar intermediolateral cells and between cells in the deep laminae of the dorsal horn. In the white matter, fine nerve fibers were dispersed in all funiculi. In the thoracolumbar region, neuronal processes of the sympathetic intermediolateral cells extended lat-

erally into the lateral funiculus.

At one postnatal week, more dense NADPH-d positive nerve fibers crossed the midline, dorsal and ventral to the central canal and in the ventral white commissure. Few cells (intercalated nucleus) were found medial to the intermediolateral cell column in the thoracolumbar region. The loosely arranged parasympathetic neurons were observed in the lateral part of lamina VII in the upper sacral segments. Small positive cells and nerve fibers appeared in lamina II of the dorsal horn. More positive cells appeared in the deep dorsal horn (laminae III, VI). NADPH-d positive nerve fibers were more condense in the deep part of the dorsal funiculus.

By the second postnatal week, the organization of the sympathetic preganglionic cells became mature; the

MANSOURA MEDICAL JOURNAL

cells became more compact and the intercalated and funicular nuclei became more prominent. In the dorsal funiculus, NADPH-d positive fibers were running mostly in a direction parallel to the midline. Some thick fibers were located along the medial margin of the dorsal horn. Positive nerve fibers in the dorsolateral funiculus became clearly observed on this week and corresponded to the spino-cervicothalamic tract.

At the third week, positive nerve fibers extending from Lissauer's tract along the lateral side of the dorsal horn to the sacral parasympathetic nucleus were observed, and all the nuclei and arrangement of the nerve fibers showing NADPH-d positivity appeared almost like those of the adult. The results of this investigation are discussed.

INTRODUCTION

Nitric oxide (NO) is a free radical gas that diffuses unhindered from cells of its origin to affect all cells in its immediate vicinity (1). This property allows NO released from nitrenergic neurons to play a universal role in modulating the release of neurotransmitters in the brain (2). Neuronal nitric oxide synthase (nNOS) is an

enzyme for generation of NO in nervous system (1,3). Nitrenergic neurons can be identified by nNOS immunohistochemistry and nicotinamide adenine dinucleotide phosphate-diaphorase (NADPH-d) histochemistry (4, 5).

In the spinal cord, NADPH-d positive neurons have been identified in neurons in distinct regions including the superficial part of the dorsal horn (lamina II), the deeper layers of the dorsal horn (laminae III-V), the pericentral area (lamina X) and the intermediolateral cell column of the thoracolumbar and sacral segments (6,7,8, 9,10,11,12). A dense plexus of NOS-positive fibers occupying the superficial dorsal horn surrounds the neurons in this layer (7).

Unfortunately, the localization and distribution of NADPH-d positive neurons and fibers in the developing spinal cord are lacking (13,14,15,16). Therefore, the present study aims to demonstrate the distribution pattern and the temporal sequence of appearance of NADPH-d positive neurons and nerve fibers in the different regions of the spinal cord. The postnatal albino rat was taken as a model.

MATERIALS AND METHODS

Fifteen albino rats were used in this study. They were divided into five groups of three rats each: 1 day, 1 week, 2 weeks, 3 weeks and 4 weeks postnatally. The rats were anesthetized with chloroform and perfused intracardially with 4% paraformaldehyde in 0.1M phosphate buffer at pH 7.4. The vertebral columns were carefully dissected and the spinal cords were carefully dissected out, kept in the same fixative for 2-3 hours at 4 °C, and kept in 0.1M phosphate buffer (pH 7.4) containing 10% sucrose overnight at 4 °C. The spinal cords were divided into cervical, thoracic, lumbar and sacral segments. Frozen cross sections (20µm) were cut in the cryostat and were then processed for NADPH-d histochemistry (17). The sections were rinsed in phosphate buffer (pH 7.4) for 10 minutes and then incubated in NADPH-incubating medium for 2 hours in the dark. The incubation medium consisted of: 2 mg/ml NADPH, 0.5 mg/ml nitroblue tetrazolium and 5% triton X-100 (Sigma) dissolved in 0.1M phosphate buffer (pH 7.4). The sections were then rinsed in 3 changes of 0.1M phosphate buffer (pH 7.4), air dried, cleared in xylene and mounted in Canada balsam.

RESULTS

One postnatal day :

Examination of the cervical, thoracic, lumbar and sacral segments of the spinal cord showed that NADPH-d intensely stained neurons were constantly present in the pericentral area (lamina X) in all segments of the spinal cord (Fig. 1). The cells were located mainly on either side of the central canal, while few cells were present ventral to it. Massive NADPH-d positive neurons appeared on the dorsal aspect of the central canal in the lumbosacral segments (Fig. 2). Some of the neuronal processes in the pericentral area appeared directed dorsally (Fig. 4). Other fine nerve fibers arising from these cells crossed to the opposite side ventral to the central canal in the ventral gray commissure, with few thin fibers in the ventral white commissure (Fig. 5).

In the intermediolateral cell column of the thoracolumbar segments (Figs. 2 & 3) and in the parasympathetic nucleus of the upper sacral segments, the positive cells showed intense NADPH-d histochemical reaction. NADPH-d positive nerve fibers were seen extending in the area between the pericentral zone and the interme-

diolateral cells. NADPH-d positive neuronal processes from the intermediolateral cells were directed laterally into the white matter (Figs. 2 & 3).

In the dorsal horn, NADPH-d positive neurons and nerve fibers were absent in the superficial layers (Fig. 6). Intensely positive multipolar neurons were seen in laminae IV-V (Figs. 6 & 7). Varicose nerve fibers were seen extending from the positive neurons (Fig. 7).

In the ventral horn, few moderately NADPH-d stained cells appeared dispersed especially at the periphery (Fig. 8).

In the dorsal funiculus, NADPH-d positive nerve fibers appeared as small dots, and were dispersed in its deep part (Fig. 9). The density of the nerve fibers was more in the cervical region than in the lumbosacral region.

In the ventral and lateral funiculi, fine widely dispersed intensely stained nerve fibers were observed.

One postnatal week :

Heavily stained NADPH-d cells

were seen surrounding the central canal in all segments of the spinal cord. Fewer cells were found on its ventral aspect and more cells on its dorsal aspect (Fig. 10). The positively stained subependymal plexus of nerve fibers and their cell bodies appeared surrounding the ependymal cells of the central canal (Fig. 11). More dense NADPH-d positive nerve fibers crossed the midline, dorsal (Fig. 12) and ventral (Fig. 13) to the central canal. The fibers crossed to the opposite side in the ventral white commissure and appeared thicker with apparent varicosity.

The sympathetic nucleus in the thoracolumbar region showed heavily stained neurons with larger cell bodies and many cell processes extending laterally and medially (Fig. 14). One or two cells appeared medial to the intermediolateral cells of the thoracolumbar region. Many blood vessels were seen in close proximity to the cells and fibers. The transverse bundles between the intermediolateral cells and pericentral zone became more apparent. The parasympathetic cells in the upper sacral region in the lateral part of lamina VII and were dispersed with no marked medial and lateral processes (Fig. 15).

Small NADPH-d positive cells appeared in the superficial layers of the dorsal horn in lamina II. Positively stained nerve fibers appeared among the cells and in Lissauer's tract (Figs. 16 & 17). Positive cells were present in laminae III- VI in the deep dorsal horn. They became larger in size with thicker arbourizing processes (Figs. 16 & 18). Few large cells appeared in the intermediate zone with their long axis and processes located in a dorsoventral direction (Fig.19).

Moderately and weakly stained neurons and few deeply stained cells were located in the ventral horn.

In the dorsal funiculus, many varicose NADPH-d positive nerve fibers were seen running parallel to the dorsal median septum in the cervical region (Fig. 20). In the thoracic region, many nerve fibers passing towards the midline were found in the deeper part of the funiculus (Fig. 21). The superficial part of the funiculus showed fewer number of positive nerve fibers.

In the ventral funiculus, two types of NADPH-d positive nerve fibers were present: thick nerves and very thin varicose ones (Fig. 22).

In the lateral funiculus, nerve fibers appeared extending from the intermediolateral cell column laterally towards the white matter.

Two postnatal weeks :

NADPH-d positive neurons were hardly detected on the ventral aspect of the central canal in the thoracic, lumbar and sacral regions. The lumbosacral segments showed the highest density of neurons dorsal to the canal. The cell processes appeared running in different directions: towards the dorsal horn, towards the central canal to form the subependymal plexus and crossing to the opposite side ventral and dorsal to the central canal (Fig. 23). The dorsal gray commissure showed many heavily stained nerve fibers (Fig. 24).

Many cells appeared medial to the intermediolateral cell column in the thoracolumbar region and their processes were directed medially towards the pericentral zone (Figs. 25 & 26). Few cells were seen extending lateral to the intermediolateral cells into the lateral funiculus (Figs. 25 & 27).

In the dorsal horn, NADPH-d positive cells located in laminae II and III

increased in number, and few cells started to appear in lamina I. More NADPH-d positive fibers were seen in the superficial layers of the dorsal horn and in Lissauer's tract (Fig. 28). Some large heavily stained cells were seen in lamina VI and their processes appeared directed dorsally and ventrally (Fig. 27).

In the ventral horn, moderately stained cells were randomly distributed.

In the dorsal funiculus, the density of the NADPH-d positive nerve fibers showed no marked difference from that of the first week. The orientation of the positive nerve fibers in the thoracic region became slightly oblique or parallel to the median septum. Few thick nerve fibers with elongated varicosities were seen passing tangential to the medial margin of the dorsal horn in the thoracolumbar region (Fig. 29).

In the dorsolateral funiculus close to the dorsolateral side of the dorsal horn, NADPH-d positive nerve fibers became more apparent (Fig. 30). In the lateral funiculus, NADPH-d positive nerve fibers appeared running in different directions; parallel to the

margin of the ventral horn in a dorso-ventral direction, along the ventral nerve rootlets towards the periphery of the cord and laterally near the intermediolateral cell column (Fig. 31). In the ventral funiculus, the fiber density appeared closer to the ventral white commissure and to the ventral horn.

Three and four postnatal weeks :

By the third postnatal week the different regions of the spinal cord acquired the adult appearance

In the thoracolumbar region, the cells of the intermediolateral cell column became more compact and the funicular neurons became more apparent (Fig. 32). NADPH-d positive cells were located along the course of the transverse processes of the intermediolateral cells towards the pericentral zone.

In the sacral region, the cells of the parasympathetic nucleus appeared more compact at the third postnatal week and their axons appeared directed ventrally towards the ventral nerve root. NADPH-d positive nerve fibers appeared extending from the lateral side of Lissauer's tract and coursed along the lateral margin of the dorsal horn

to reach the parasympathetic nucleus (Figs. 33 & 34).

In the superficial dorsal horn, NADPH-d positive nerve fibers became more dense (Fig. 35) and appeared almost similar to those of the adult (Fig. 36). Heavily stained nerve

fibers were located along the Lissauer's tract.

In the dorsal funiculus, the varicosity of the nerve fibers became more apparent (Fig. 37). No marked changes were present in the ventral and lateral funiculi (Fig. 38).

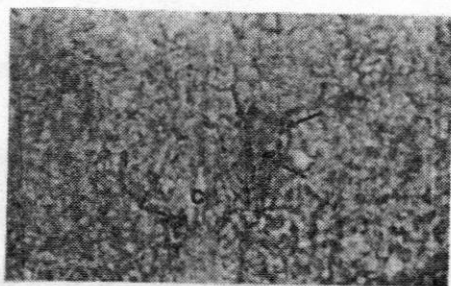


Fig. 1 Cervical segment at one post-natal day showing NADPH-d strongly positive neurons in the pericentral zone (arrows) around the central canal (c). X 100




Fig. 2 Lumbar segment at one post-natal day showing massive concentration of NADPH-d positive neurons in the dorsal gray commissure (arrowhead) behind the central canal (c). Note the transverse processes (arrows) extending between the intermediolateral cells (IML) and the dorsal gray commissure cells. X 100

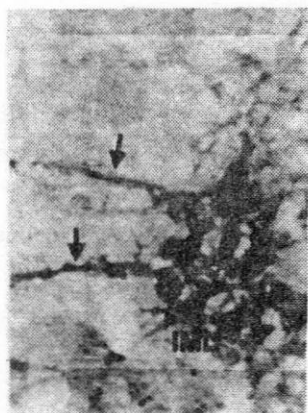


Fig. 3 Higher magnification of Fig. 2. showing loosely arranged intensely positive intermediolateral cells (IML). Positive nerve fibers extend laterally towards the lateral funiculus of the white matter (arrows). X 400

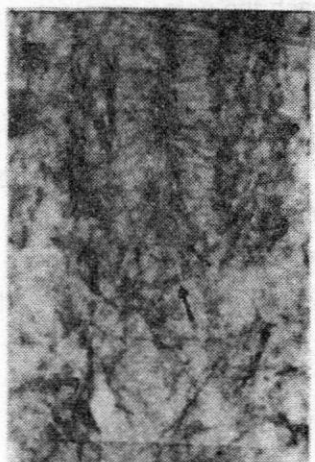


Fig. 5 Fine nerve fibers (arrows) crossing ventral to the central canal (c) in a sacral segment of one postnatal day rat. X 400

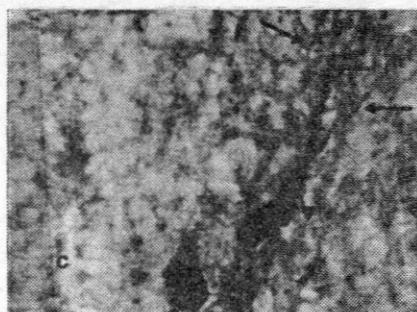


Fig. 4 Pericentral zone of a cervical segment at one postnatal day showing strongly positive cell (arrowhead) and its processes extending dorsally (arrows); central canal (c). X 400



Fig. 6 Dorsal horn of a lumbar segment at one postnatal day showing strongly positive neurons in laminae IV-V (arrows). Note absence of neurons in the superficial laminae. X 100

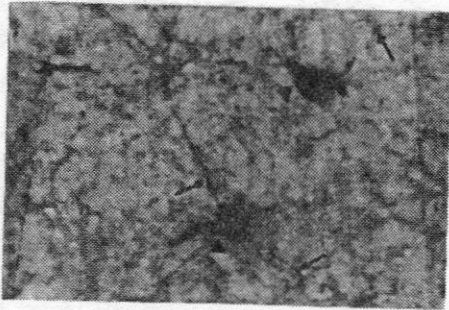


Fig. 7 NADPH-d positive neurons (arrowheads) in laminae IV-V of a cervical segment at one postnatal day. They have varicose processes (arrows). X 400




Fig. 9 Dorsal funiculi of a lumbar segment at one postnatal day showing scattered NADPH-d positive nerve fibers (arrows). Note the positive nerve fibers running tangential to the medial margin of the dorsal horn (arrowheads). X400

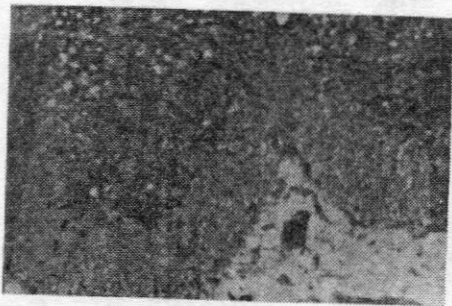

Fig. 8 Ventral horn of a thoracic segment at one postnatal day showing scattered moderately stained neurons at the periphery (arrows). X 100




Fig. 10 Pericentral zone of a cervical segment at one postnatal week. Note the larger size of cell bodies (arrows); central canal (c). X100

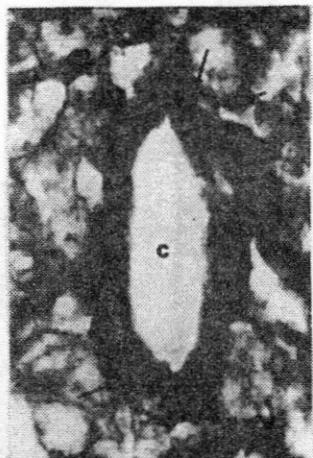


Fig. 11 Cervical segment at one postnatal week showing the subependymal plexus of nerves and the thicker processes (arrows) of neurons around the central canal (c). X400

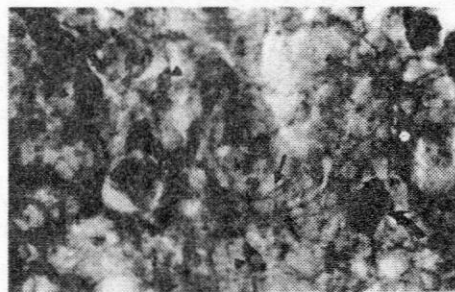


Fig. 13 NADPH-d positive nerve fibers are seen crossing ventral (arrows) to the central canal (C) in a cervical segment at one postnatal week. Note smaller moderately stained cells (arrowheads) and larger deeply stained cells (curved arrows) in close relation to the central canal (c). X40

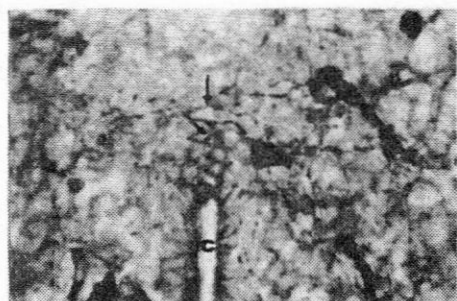

Fig. 12 NADPH-d positive nerve fibers (arrows) are seen crossing in the dorsal gray commissure dorsal to central canal (c) in a lumbar segment at one postnatal week. X400

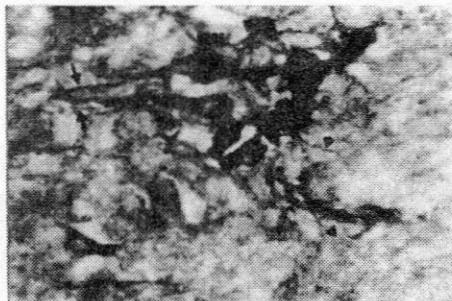


Fig. 14 Intermediolateral cells (IML) in a thoracic segment at one postnatal week. Note the intensely stained cell bodies and their neuronal processes appear directed medially (arrows) and laterally (arrowheads). X40

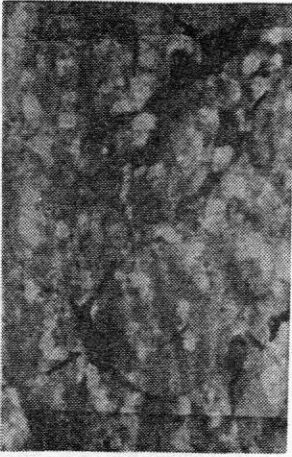

Fig. 15 NADPH-d positive neurons in the parasympathetic nucleus at the lateral end of lamina VII in a sacral segment at one postnatal week (arrows). Note that there is no marked medial and lateral neuronal processes. X400



Fig. 17 Lamina II of a cervical segment at one postnatal week. Note the intensely stained nerve cell bodies and the thin NADPH-d positive nerve fibers among the cells (arrows). X400

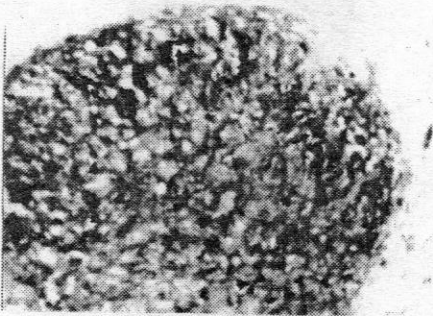


Fig. 16 Dorsal horn of a cervical segment at one postnatal week showing small NADPH-d positive cells in lamina II (arrows). Note the presence of larger cells in laminae III, IV (arrowheads). X100

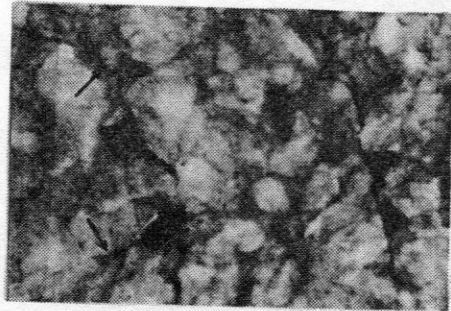


Fig. 18 NADPH-d positive cells in lamina IV-V of a cervical segment at one postnatal week. Note the larger size of neurons and the thicker processes (arrows). X400

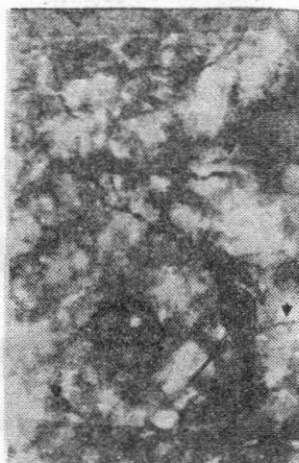


Fig. 19 A large strongly positive neuron is present in lamina VII of a lumbar segment at one postnatal week (arrow). Its cell processes pass dorsally and ventrally. Note the medially directed cell processes of the intermediolateral cells (arrowheads). X400

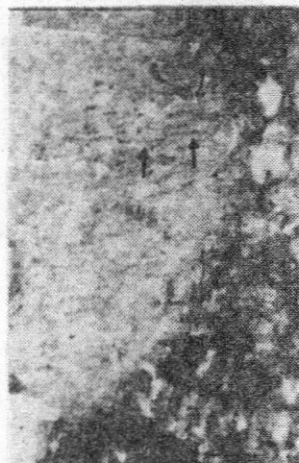

Fig. 21 Dorsal funiculus of a thoracic segment at one postnatal week. Note NADPH-d positive nerve fibers (arrows) running mostly in a latero-medial direction especially in the middle third of the funiculus. X400

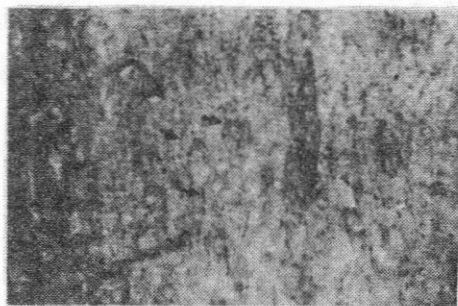


Fig. 20 Dorsal funiculi of a cervical segment at one postnatal week showing positive nerve fibers running mostly in a direction parallel to the midline (arrows). X400

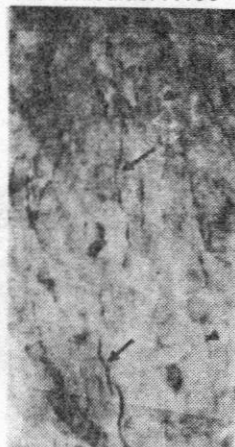


Fig. 22 Ventral funiculus of a cervical segment at one postnatal week. Two types of NADPH-d positive nerve fibers are present; one thick (arrows) and one thin varicose (arrowheads). X400

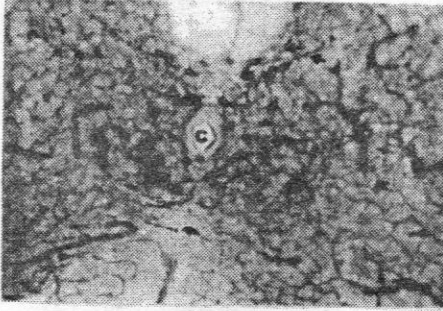


Fig. 23 Pericentral zone of a cervical segment at two postnatal weeks. The cell processes are running in different directions: towards the dorsal horn (arrows), towards the central canal to form the subependymal plexus (arrowheads) and crossing to the opposite side ventral and dorsal to the central canal (c). X100

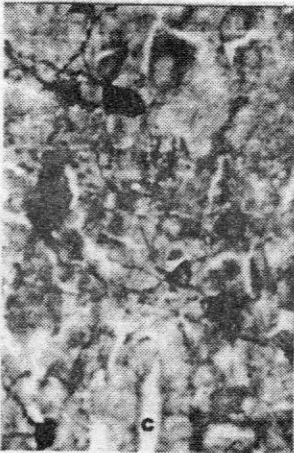


Fig. 24 Dorsal gray commissure of a lumbar segment at two postnatal weeks. Note the thick plexus of NADPH-d positive nerve fibers dorsal to the central canal (c). X400

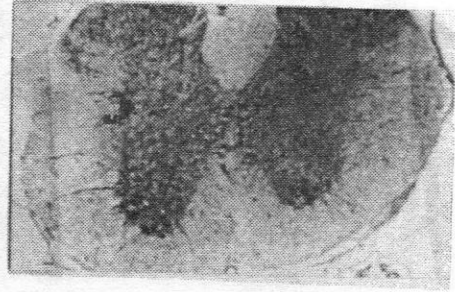


Fig. 25 Thoracic segment at two postnatal weeks showing NADPH-d positive cells (arrows) medial to the intermediolateral cells (IML) and others projecting into the lateral funiculus (arrowheads). X40

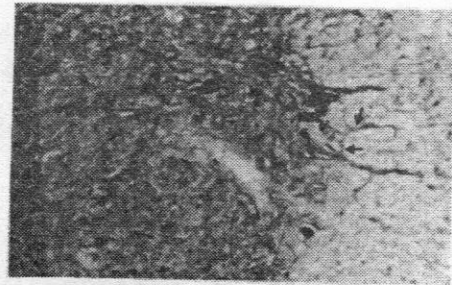


Fig. 26 NADPH-d positive cells are present medial to the intermediolateral cells (IML) in a lumbar segment at two postnatal weeks. Their cell processes are medially directed (arrowheads). Note the close relation of the cells of intermediolateral column and blood vessels (arrows). X100

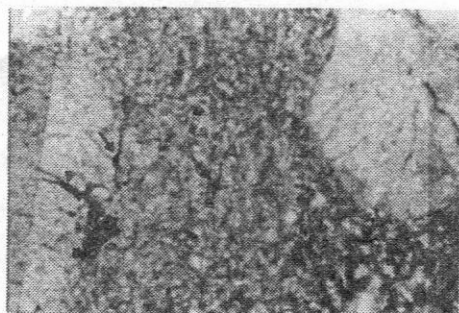


Fig. 27 NADPH-d strongly positive cells are seen in laminae IV-VI of thoracic segment at two postnatal weeks. Those in lamina VI (arrows) have processes directed dorsally and ventrally. Note the cells (arrowhead) lateral to the intermediolateral cells (IML) in the lateral funiculus. X100

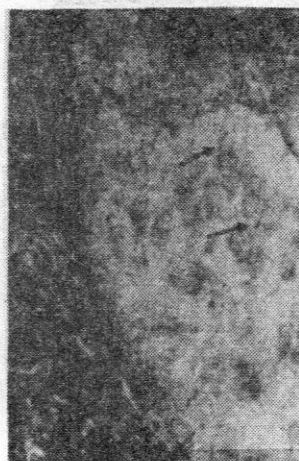

Fig. 29 Dorsal funiculus of a thoracic segment at two postnatal weeks showing NADPH-d positive nerve fibers running in a direction mostly parallel to the midline (arrows). Note the thick strongly positive nerve fibers running along the medial margin of the dorsal horn (arrowheads). X400

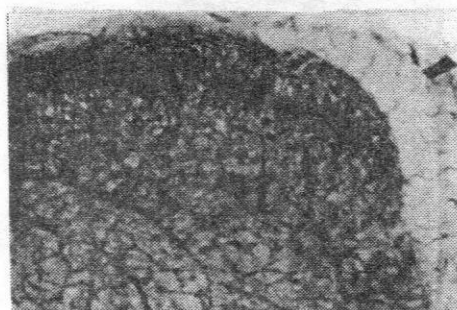


Fig. 28 Dorsal horn of a cervical segment showing increased number of NADPH-d positive cells in lamina II and III (arrows). Note dense plexus of positive nerve fibers in lamina II. X100

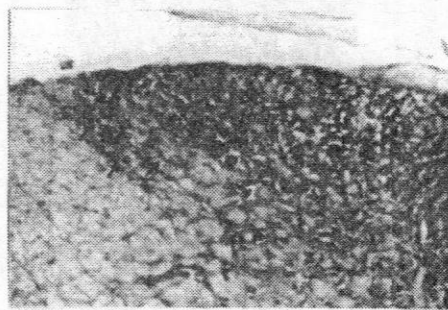


Fig. 30 NADPH-d positive nerve fibers (arrows) are present in the dorsolateral funiculus lateral to the dorsal horn in a cervical segment at two postnatal weeks. X100

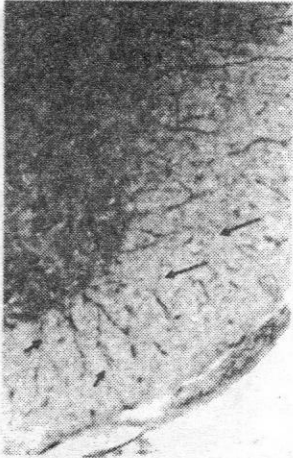


Fig. 31 Lateral funiculus of a thoracic segment at two postnatal weeks showing positive nerve fibers running in different directions: parallel to the margin of ventral horn (long arrows), along the ventral rootlets (short arrows) and laterally near the intermediolateral cell column (arrowheads). X100

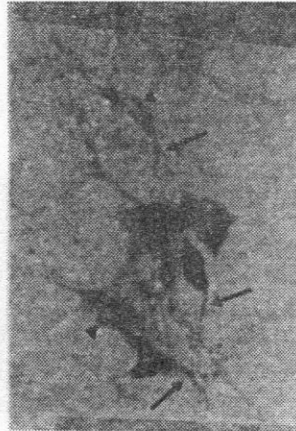

Fig. 33 Sacral para-sympathetic neurons (arrowheads) at three postnatal weeks. The axons of the cells are directed ventrally (arrows). X400

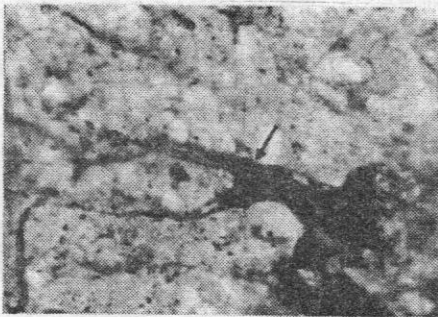


Fig. 32 Intermediolateral cells (IML) of a thoracic segment at four postnatal weeks showing more compact arrangement of neurons. Note the funicular cells (arrow) that project laterally. X400

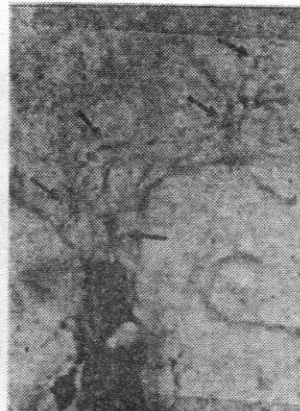

Fig. 34 NADPH-d positive nerve fibers (arrows) passing along the lateral aspect of the dorsal horn to the sacral parasympathetic neurons at three postnatal weeks. X400

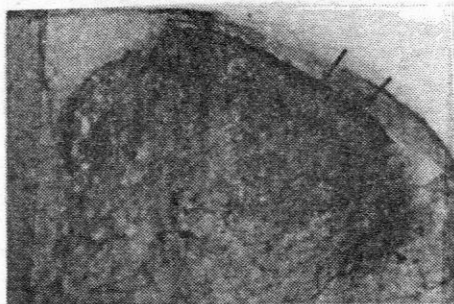


Fig. 35 Dorsal horn of a thoracic segment at three postnatal weeks showing intensely positive nerve fibers along Lissauer's tract (arrows). Note positive nerve fibers are seen in the dorsolateral funiculus (arrowheads). X100

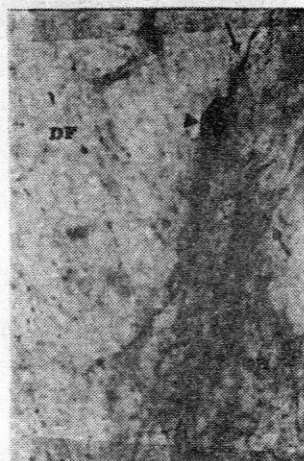

Fig. 37 Dorsal funiculus (DF) of a cervical segment at four postnatal weeks. Note the strongly positive cell (arrowhead) and nerve fibers (arrows) along the medial margin of the dorsal horn (DH). X400

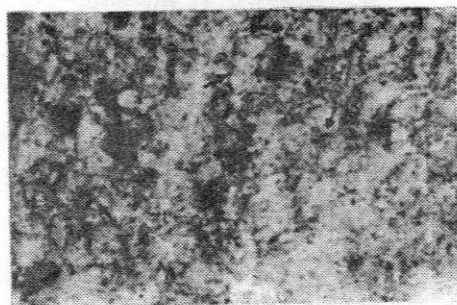


Fig. 36 Lamina II of a cervical dorsal horn at four postnatal weeks showing intensely stained nerve fibers running in different directions (arrows). X400




Fig. 38 Lateral funiculus of a cervical segment at three postnatal weeks. Note the marked varicosity of the nerve fibers running parallel to the lateral margin of the ventral horn (arrowheads) and sympathetic nerve fibers passing laterally (arrows). X40

DISCUSSION

The freely diffusible radical gas nitric oxide (NO) is a neuronal messenger that modulates neuronal function. It modulates the release of several neurotransmitters, such as acetylcholine, catecholamines, excitatory and inhibitory amino acids, serotonin, histamine and adenosine (2). Nitroergic neurons detected by nitric oxide synthase (NOS) immunohistochemistry and NADPH-d histochemistry are confined to certain regions of the spinal cord. These include the pericentral zone, the intermediolateral cell column and the superficial and deep dorsal horn (6,7,8,9,10,11,12).

In the present study, NADPH-d intensely stained neurons appeared at birth in the pericentral zone in all segments of the spinal cord, in the intermediolateral cell column of thoracolumbar segments and the upper sacral segments. These neurons in the intermediolateral cell column represent the sympathetic nucleus in the thoracolumbar region and the parasympathetic nucleus in the sacral region. These observations correspond with the previously published reports (14, 15, 16).

In the sympathetic system, four

subnuclei have been identified; the principal intermediolateral nucleus (ILP) in the lateral horn, the central autonomic cell column (CA) dorsal to the central canal, the intercalated nucleus (IC) located between ILP and CA, and the funicular intermediolateral neurons in the white matter lateral to the ILP (18,19,20,21,22). In the present study, few cells in the intercalated nucleus and the funicular intermediolateral neurons appeared at birth and became more compact by the age of two weeks. This may indicate that the organization of the sympathetic nuclei reached the adult form two weeks postnatally, supporting the observation of Pyner & Coote (23). The transverse dendritic bundles formed by the medially directed dendrites of the ILP nucleus and the IC nucleus and the laterally directed dendrites of CA and the ILP nucleus were prominent at birth. This indicates that the medial core circuit and paralateral circuit which may convey supraspinal afferent inputs to the sympathetic preganglionic neurons were already present at birth and may represent potential sites of interaction with incoming segmental and/or descending inputs (24, 25).

On the other hand, the present re-

sults revealed that the parasympathetic neurons were present in the lateral part of lamina VII and were absent near the central canal. This supports the observation of Kluchova et al. (11).

The visceral afferents to the spinal cord are distributed over Lissauer's tract to a medial and a lateral collateral pathway. The medial collateral pathway ends in the medial regions of lamina I and IIa and few axons continue further to laminae V and X (26). In the present study, NADPH-d positive nerve fibers were present at birth flanking the medial margin of the dorsal horn in the thoracolumbar region. These fibers may represent the medial collateral pathway. No positive nerve fibers could be traced on the lateral margin of dorsal horn to lamina V or sympathetic preganglionic nucleus (lateral collateral pathway). Similarly, Doone et al. (27) noticed absence of NADPH-d positive fibers in the lateral collateral pathway in the thoracolumbar segments of adult guinea pig. On the contrary, Foster & Phelps (28) described diaphorase positive nerve fibers coursing along the lateral aspect of the dorsal horn of the developing human thoracolumbar spinal cord.

In the rat, the present results showed the presence of NADPH-d positive nerve fibers in the lateral collateral pathway ending in the region of the parasympathetic nucleus in the upper sacral segments at three postnatal weeks. The late expression of NO in the lateral collateral pathway in the sacral segments may be related to maturation of pelvic visceral reflex pathways including micturition (14).

The close association between blood vessels and NADPH-d positive neurons in the adult intermediolateral cell column (7, 29) was evident by the first postnatal week. This relationship suggests that NO may help to couple neural activity with regional blood flow in the spinal cord (7).

In this investigation, NADPH-d positivity was observed in the nerve fibers of the subependymal plexus around the central canal and in the nerve fibers traversing the ependymal cells. These nerve fibers became apparent by the first postnatal week. It has been suggested that the distribution of these nerve fibers close to the central canal may indicate that NO may be released into the cerebrospinal fluid (21).

Examination of the dorsal horn revealed the presence of NADPH-d positive neurons in the deep laminae (IV-V) at birth. Some positively stained cells appeared in laminae III and VI in the first week. Spike et al. (30) and Wetts and Vaughn (31) reported that in the adult spinal cord more than 50% of the diaphorase labeled cells in lamina III-V were double labeled with choline acetyltransferase (ChAT). These, double labeled, cells were found to arise from the U-shaped group of cells derived from the ventral ventricular zone (32, 33) while the diaphorase only cells arose from the dorsal ventricular zone and achieved their adult location by the 8-15th postnatal day (15). The expression of NO in some populations of neurons as they migrate to their final positions may reflect a role in neuronal development (33). Neuronal NOS/NO system has been shown to be involved in the dorsal horn nociceptive pathways (34). C-fiber-evoked response of wide dynamic range neurons in the deep dorsal horn became mature and functional from postnatal day 14 (35). This coincides with functional maturity in NADPH-d positive neurons.

Corresponding with previously

published observations (14,15,16), the NADPH-d positive neurons and fibers in the superficial dorsal horn appeared relatively late postnatally. This may indicate that NOS and its product, NO, are unlikely to be involved in the ingrowths of axons to, and synaptogenesis in, this region. Rather this late appearance may reflect the functional maturation of the sensory pathways subserved by this region and the segmental and supraspinal interactions with these pathways (13).

Animal experiments demonstrated a visceral nociceptive pathway in the posterior column that was more effective than the spinothalamic tract in activating thalamic neurons and triggering increases in regional cerebral blood flow. This visceral nociceptive pathway involves postsynaptic dorsal column neurons in the central, visceral processing region of the spinal cord. Axons from the sacral cord ascend near the midline and those from the thoracic cord ascend at the junction of the gracile and cuneate fasciculi (36,37). Spinal afferents to the central gray and surrounding area arise from laminae III-IV (38). Previous studies suggested a role of nitric oxide as a neurotransmitter within the

visceral afferent pathway (7,8,39). As nitric oxide was shown to be involved in nociception at the spinal level (40), the presence of NADPH-d positive fibers in the dorsal funiculus may belong to the visceral nociceptive pathway. This needs more investigations as the positive nerve fibers were dispersed in the dorsal funiculus especially in its deep part, which does not match closely the localization of the visceral nociceptive pathway described by previous works.

By the second postnatal week, NADPH-d positive nerve fibers were apparent in a region corresponding to the spinocervicothalamic tract on the extreme lateral edge of the dorsal-most portion of the lateral funiculus (dorsolateral funiculus). This tract ends in the lateral cervical nucleus of the rat, which is restricted to a region in the dorsolateral funiculus within spinal segment C2. The nucleus receives inputs from the ipsilateral nucleus proprius at all levels of the spinal cord but were most numerous in the cervical enlargement (41). The tract carries noxious mechanical information (42). Therefore, the observation of NADPH-d positive fibers in this region may indicate that NO may play a role in this pathway which

became mature by the second postnatal week.

In the ventro-lateral funiculus, NADPH-d positive nerve fibers running in different directions were identified at birth. They included the mediolaterally directed dendrites of the sympathetic intermediolateral cell column, the autonomic axons passing along the ventral rootlets and fine nerves deeply located parallel to the margins of the ventral horn. It has been suggested that reticulospinal NADPH-d-positive axons, without forming well-defined tracts, along with propriospinal NADPH-d-positive axons, are intermingled with ascending and descending fibers of other systems (43, 44). However, the origin of a large proportion of NADPH-d positive axons ascending or descending in the lateral funiculus still remain unclear (44).

The localization of NO in specific populations of the spinal cord neurons indicates that it is involved in processing autonomic, somatosensory and visceralsensory information in the spinal cord (7, 8, 39, 45). The early appearance of NO in some neurons, suggests that NO may play an important role during development, which

may differ from its function in the adult nervous system (15).

Acknowledgement

The author would like to thank Prof. Dr. Adel A. Bondok, Prof. of Anatomy, for critically reviewing the manuscript and for his useful comments.

REFERENCES

1. **Bred DS, Snyder SH (1992) :** Nitric oxide, a novel neuronal messenger. *Neuron* 8: 3-11.
2. **Prast H, Philippu A (2001) :** Nitric oxide as modulator of neuronal function. *Prog Neurobiol.* May;64(1):51-68
3. **Vincent SR, Hope BT (1992) :** Neurons that say NO. *Trends in Neuroscience* 15: 108-113
4. **Dawson TM, Bredt DS, Fotuhi M, Hwang PM, Snyder SH (1991) :** Nitric oxide synthase and neuronal NADPH diaphorase are identical in brain and peripheral tissues. *Proc Natl Acad Sci USA* 88: 7797-7801.
5. **Hope BT, Michael GJ, King KM, Vincent SR (1991) :** Neuronal NADPH diaphorase is a nitric oxide synthase. *Proc Natl Acad Sci USA* 88: 2811-2814
6. **Dun NJ, Dun SL, Forstermann U, Tseng LF (1992) :** Nitric oxide synthase immunoreactivity in rat spinal cord. *Neurosci. Lett.* 147: 217-220
7. **Valtschanoff JG, Weinberg RJ, Rustioni A (1992) :** NADPH diaphorase in the spinal cord of rats. *J. Comp. Neurol.* 321: 209-222
8. **Saito S, Kidd GJ, Trapp BD, Dawson TN, Bredt DS, Wilson DA, Traystman RJ, Snyder, SH, Hanley DF (1994) :** Rat spinal cord neurons contain nitric oxide synthase. *Neuroscience* 59: 447-456
9. **Marsala J, Kluchova D, Marsala M (1997) :** Spinal cord gray matter layers rich in NADPH diaphorase positive neurons are refractory to ischemia-reperfusion-induced injury: a

- histochemical and silver impregnation study in rabbit. *Exp Neurol* 145: 165-179
10. Kluchova D, Rybarova S, Schmidtova K, Kocisova M, Dorko F (1997) : The activity of NADPH-diaphorase in rabbit spinal cord. *Folia Med Cass* 54: 35-44
11. Kluchova D, Schmidtova K, Dorko F, Pomfy M (1998) : NADPH-diaphorase activity in autonomic preganglionic neurons in the rabbits. *Bratisl Lek Listy* 99(5): 267-272
12. Kluchova D, Schmidtova K, Rybarova S, Lovasova K, Pomfy M, Prosbova T, Vatlav A (2000) : Partial colocalization of NADPH-diaphorase and acetylcholinesterase positivity in spinal cord neurons. *Physiol. Res.* 49: 151-155
13. Liuzzi FJ, Wu W, Scoville SA, Schinco FP (1993) : Development of nitric oxide synthase expression in the superficial dorsal horn of the rat spinal cord. *Exp Neurol* Jun; 121(2): 275-278
14. Vizzard MA, Erdman SL, Forsterman U, de Groat WC (1994) : Ontogeny of nitric oxide synthase in the lumbosacral spinal cord of the neonatal rat. *Brain Res Dev Brain Res.* Sep 16; 81(2): 201-217
15. Wetts R, Phelps PE, Vaughan JE (1995) : Transient and continuous expression of NADPH diaphorase in different neuronal populations of developing rat spinal cord. *Dev Dyn.* Mar; 202(3): 215-228
16. Takemura M, Wakisaka S, Iwase K, Yabuta NH, Nakagawa S, Chen K, Bae YC, Yoshida A, Shigenaga Y (1996) : NADPH-diaphorase in the developing rat: lower brainstem and cervical spinal cord, with special reference to the trigemino-solitary complex. *J Comp Neurol.* Feb 19; 365(4): 511-525
17. Scherer-Singler U, Vincent SR, Kimura H, McGeer EG

- (1983) : Demonstration of a unique population of neurons with NADPH-diaphorase histochemistry. *J Neurosci Meth* 9:229-234
18. **Deuschl G, Illert M. (1981)** : Cytoarchitectonic organization of lumbar preganglionic sympathetic neurons in the cat. *J Auton Nerv Syst.* Apr;3(2-4):193-213.
19. **Barber RP, Phelps PE, Houser CR, Crawford GD, Salvatore PM, Vaughn JE. (1984)** : The morphology and distribution of neurons containing choline acetyltransferase in the adult rat spinal cord: an immunocytochemical study. *J Comp Neurol.* Nov1; 229(3):329-46.
20. **Davidoff MS, Galabov PG, Bergmann M. (1989)** : The vegetative network in the thoracolumbar spinal cord of the guinea pig: a comparison of the distribution of AChE-enzyme activity and choline acetyltransferase-like immunoreactivity. *J Hirnforsch.* 30(6):707-17.
21. **Tang FR, Tan CK, Ling EA (1995b)** : The distribution of NADPH-d in the central gray region (lamina X) of rat upper thoracic spinal cord. *J Neurocytol.* Oct; 24(10): 735-743
22. **Reuss MH, Reuss S (2001)** : Nitric oxide synthase neurons in the rodent spinal cord: distribution, relation to substance P fibers, and effects of dorsal rhizotomy. *J Chem Neuroanat.* Mar;21(2):181-196
23. **Pyner S, Coote JH. (1994)** : A comparison between the adult rat and neonate rat of the architecture of sympathetic preganglionic neurons projecting to the superior cervical ganglion, stellate ganglion and adrenal medulla. *J Auton Nerv Syst.* Jul;48(2):153-66.
24. **Shen E, Dun NJ. (1990)** : Neonate rat sympathetic preganglionic neurons intracellularly labelled with lucifer

- yellow in thin spinal cord slices. *J Auton Nerv Syst.* Mar;29(3):247-54.
25. **Tang FR, Tan CK, Ling EA (1995a)** : A light-microscopic study of the intermediolateral nucleus following injection of CB-HRP and fluorogold into the superior cervical ganglion of the rat. *J Auton Nerv Syst.* Jan 3;50(3):333-8.
26. **Neuhuber WL, Sandoz PA, Fryszak T. (1986)** : The central projections of primary afferent neurons of greater splanchnic and intercostal nerves in the rat. A horseradish peroxidase study. *Anat Embryol (Berl)*.174(1):123-44.
27. **Doone VG, Pelisser N, Manchester T, Vizzard AM. (1999)** : Distribution of NADPH-d and nNOS-IR in the thoracolumbar and sacrococcygeal spinal cord of the guinea pig. *J Auton Nerv Syst.* Sep 24;77(2-3):98-113
28. **Foster JA, Phelps PE. (2000a)** : NADPH-diaphorase reveals presumptive sympathetic primary afferents in the developing human spinal cord. *Auton Neurosci.* Oct 30; 84(1-2):111-117
29. **Marsala J, Marsala M, Vaniky I, Taira Y (1999)** : Localization of NADPHd-exhibiting neurons in the spinal cord of the rabbit. *J Comp Neurol.* Apr 5; 406(2):263-284
30. **Spike RC, Todd AJ, Johnston HM (1993)** : Coexistence of NADPH diaphorase with GABA, glycine, and acetylcholine in rat spinal cord. *J. Comp. Neurol.* 342:174-185.
31. **Wetts R and Vaughn JE (1994)** : Choline acetyltransferase and NADPH diaphorase are co-expressed in rat spinal cord neurons. *Neuroscience* 63:1117-1124.
32. **Phelps PE, Barber RP, Vaughn JE (1996)** : Nonradial migration of interneurons can be experimentally altered in spinal cord slice cultures.

Development 122: 2013-2022

- 33. Foster JA, Phelps PE. (2000b) :** Neurons expressing NADPH-diaphorase in the developing human spinal cord. *J Comp Neurol.* 2000 Nov 20; 427(3):417-427.
- 34. Douglas W. Zochodne, Hong Sun and Xia-Qing Li (2001) :** Evidence that nitric oxide- and opioid-containing interneurons innervate vessels in the dorsal horn of the spinal cord of rats *J Physiol* 532 (3) :749-758
- 35. Urch CE, Dickenson AH. (2003) :** Neuronal nitric oxide synthase modulation of dorsal horn neuronal responses in the rat: a developmental study. *Dev Neurosci.* Sep-Oct; 25(5):301-7
- 36. Willis WD Jr, Westlund KN (2001) :** The role of the dorsal column pathway in visceral nociception. *Curr Pain Headache Rep.* Feb; 5(1):20-26
- 37. Palecek J, Paleckova V, Willis WD (2002) :** The roles of pathways in the spinal cord lateral and dorsal funiculi in signaling nociceptive somatic and visceral stimuli in rats. *Pain Apr;* 96(3):297-307
- 38. Palecek J, Paleckova V, Willis WD. (2003) :** Fos expression in spinothalamic and postsynaptic dorsal column neurons following noxious visceral and cutaneous stimuli. *Pain.* Jul;104(1-2):249-57.
- 39. Vizzard MA, Erdman SL, de Groat WC (1993) :** Localization of NADPH-diaphorase in pelvic afferent and efferent pathways of the rat. *Neurosci Lett.* Apr 2;152(1-2):72-6.
- 40. Riedel W, Neeck G. (2001) :** Nociception, pain, and antinociception: current concepts. *Z Rheumatol.* Dec; 60(6):404-15.
- 41. Baker ML & Giesler GJ Jr (1984) :** Anatomical studies

- of the spinocervical tract of the rat. *Somatosens Res.* 2(1):1-18.
42. **Kajander KC, Giesler GJ Jr (1987)** : Responses in the lateral cervical nucleus of the cat to noxious cutaneous stimulation. *J Neurophysiol.* Jun;57(6):1686-1704
43. **Nathan, P. W., Smith, M., and Deacon, P. (1996)** : Vestibulospinal, reticulospinal and descending propriospinal nerve fibres in man. *Brain* 119:1809-1833.
44. **Marsala J, Marsala M, Lukacova N, Ishikawa T, Cizkova D. (2003)** : Localization and distribution patterns of nicotinamide adenine dinucleotide phosphate diaphorase exhibiting axons in the white matter of the spinal cord of the rabbit. *Cell Mol Neurobiol.* Feb; 23(1): 57-92
45. **Bruning G. (1992)** : Localization of NADPH diaphorase, a histochemical marker for nitric oxide synthase, in the mouse spinal cord. *Acta Histochem.* 93(2):397-401.

ظهور إنزيم النيتريك أوكسيد سينشاز فى الحبل الشوكى للفأر الأبيض بعد الولادة-دراسة هيستوكيميائية

د. منى عبد الرحيم الشحات

قسم التشريح - كلية الطب - جامعة المنصورة

لقد تمت دراسة تطور ظهور إنزيم النيتريك أكسيد سينشاز بالحبل الشوكى فى الفئران البيضاء بعد الولادة باستخدام النيكوتين اميد أدينين داي نيوكليوتايد فوسفات ديافوريز هيستوكيمستري. وقد وجدت خلايا عصبية ذات تفاعل موجب قوى عند اليوم الأول بعد الولادة فى المنطقة المحيطة بالقناة المركزية وفى منطقة الخلايا السيمباثاوية والباراسيمباثاوية وأيضاً فى المناطق الداخلية (الطبقات الرابعة والخامسة) من القرن الظهري. أما فى منطقة القرن الباطنى فقد تناثرت خلايا متوسطة الإيجابية. وتواجدت الأعصاب ذات التفاعل الموجب فى المنطقة المحيطة بالقناة المركزية وبعضها كان يعبر إلى الجهة الأخرى، وأيضاً امتدت الأعصاب بين المنطقة المركزية والخلايا السيمباثاوية، وكذلك بين الخلايا الداخلية فى القرن الظهري. وقد وجدت أعصاب دقيقة ذات تفاعل موجب متناثرة فى المادة البيضاء. وفى المنطقة الصدر - قطنية امتدت الزوائد العصبية للخلايا السيمباثاوية للجانب داخل المادة البيضاء الجانبية.

وفى الأسبوع الأول كانت الأعصاب التى تعبر من أمام ومن خلف القناة المركزية وفى المنطقة الرابطة الأمامية أكثر كثافة. وقد ظهرت بعض الخلايا على الناحية الوسطية للخلايا السيمباثاوية فى المنطقة الصدر - قطنية. وكانت الخلايا الباراسيمباثاوية فى المنطقة الجانبية من الطبقة السابعة فى المنطقة العصبية متباعدة. وقد ظهرت خلايا صغيرة ذات تفاعل موجب فى الطبقة الثانية من القرن الظهري. وجدت خلايا موجبة أكثر فى الطبقات الداخلية من القرن الظهري (الطبقات ٣ و٦).

وفى الأسبوع الثانى كانت الأنوية السيمباثوية قد وصلت مرحلة النضج فأصبحت الخلايا متراصة أكثر والأنوية أوضح.. وقد وجد فى المنطقة الظهرية من المادة البيضاء أن الأعصاب الموجبة تتواجد فى اتجاه غالباً ما يوازي الخط الوسطى للحبل الشوكى. ووجدت بعض الأعصاب الموجبة السمكية على الحافة الوسطية للقرن الظهري. وفى المنطقة الخارجية الظهرية من المادة البيضاء الجانبية أصبحت الأعصاب ذات التفاعل الموجب ظاهرة أكثر.

وفى الأسبوع الثالث ظهرت أعصاب ذات تفاعل موجب ممتدة من حزمة ليساور العصبية إلى منطقة النواة الباراسيمباثاوية. وفى هذا الأسبوع وصلت كل الأنوية وترتيب الأعصاب إلى مرحلة النضج. ولقد نوقشت نتائج هذه الدراسة.

