



INDICATIONS AND COMPLICATIONS OF PNEUMONNECTOMY IN CHILDREN

Mohamed Regal

Lecturer of Cardio-thoracic Surgery Mansoura Faculty of Medicine, Mansoura, Egypt King Fahd Specialist Hospital, Buridah, Saudi Arabia

Follow this and additional works at: <https://mmj.mans.edu.eg/home>

Recommended Citation

Regal, Mohamed (2004) "INDICATIONS AND COMPLICATIONS OF PNEUMONNECTOMY IN CHILDREN," *Mansoura Medical Journal*: Vol. 33 : Iss. 1 , Article 8.
Available at: <https://doi.org/10.21608/mjmu.2004.127433>

This Original Study is brought to you for free and open access by Mansoura Medical Journal. It has been accepted for inclusion in Mansoura Medical Journal by an authorized editor of Mansoura Medical Journal. For more information, please contact mmj@mans.edu.eg.

INDICATIONS AND COMPLICATIONS OF PNEUMONNECTOMY IN CHILDREN

By
Mohamed Regal

From
Lecturer of Cardio-thoracic Surgery
Mansoura Faculty of Medicine, Mansoura, Egypt
King Fahd Specialist Hospital, Buridah, Saudi Arabia

ABSTRACT

OBJECTIVES : Pneumonectomy in children is a rare procedure, although various types of pulmonary resections are done daily for patients in this age group. We have reviewed our experience in the last 9 years, to outline the indications and identify the complications of pneumonectomy in our locality. We compared our results with the scanty information in the published literature.

Methods : From January, 1995 to December, 2003 we performed 20 pneumonectomies in children 15 years and younger. These cases were done in Mansoura University Hospitals (MUH) and King Fahd Specialist Hospital (KFSH). There were 8 males and 12 females, their ages ranged from 4 days to 15 years.

Pneumonectomies were done through the classical posterolateral thoracotomy in the 4th or 5th intercostal space.

RESULTS : The indications for pneumonectomy were destroyed lung 6 cases (30%), bronchiectasis 4 cases (20%), acquired main bronchial stricture 3 cases (15%), congenital pulmonary abnormalities 2 cases (10%), severe traumatic lung laceration 2 cases (10%), carcinoid tumors 2 cases (10%) and failed repair of avulsed left main bronchus 1 case (5%).

There was a single mortality in this series and it was related to the severity of the trauma, and not related to the pneumonectomy. There were no intraoperative complications, while immediate postoperative complications

included superficial wound infection in 1 case (5%), acute pulmonary edema in 1 case (5%), and post-pneumonectomy syndrome in 1 case (5%) which required re-operation. In the period of the follow up there was no delayed complications in our group of patients.

CONCLUSION : Careful preparation and selection of the patients for pneumonectomy, decreases the mortality and morbidity of this procedure. Early diagnosis and management of postoperative complications is essential to make the procedure safe in childhood.

Keywords : Pneumonectomy • Children • Carcinoids • Postpneumonectomy syndrome

INTRODUCTION

Resections of the lung may vary from a small pneumonotomy for enucleation of a hamartoma to a pneumonectomy (1,2). The first successful staged pneumonectomy was done with mass ligation of the hilar structures in a 12 years old girl with bronchiectasis by Nissen in 1931. The first successful one stage pneumonectomy was reported by Graham and Singer in 1933. Lung resections and pneumonectomy are an infrequent

procedures in the pediatric population compared to adults (3,4). Reviewing the published literature gives very few reports about pneumonectomy in children. The indications for pneumonectomy in children included infective conditions, irreversibly destroying the lung parenchyma (3, 5, 6, 7). Children with mycobacterial disease rarely required resectional lung surgery nowadays, due to the introduction of new antibiotics and anti tuberculous medications which controlled many of such cases (3,8,9).

Congenital pulmonary malformations occasionally require pneumonectomy, and usually managed by lesser pulmonary resections (3,5,10,11,12). Tumors and trauma are also rarely managed by pneumonectomy. A small number of trauma patients with penetrating thoracic trauma will require formal pulmonary resections to repair severe lung lacerations or control massive bleeding (13, 14).

The major life threatening intraoperative surgical complications are injury to a major vessel with massive hemorrhage, cardiac arrhythmias, development of a contralateral pneumothorax and intraoperative pulmo-

nary edema (1).

The most commonly reported post pneumonectomy complications were empyema, bleeding, bronchopleural fistulae and wound sepsis (15,16,17,18).

In order to decrease the morbidity and mortality after pulmonary resections, the surgeon should be able to recognize and manage adequately these complications (19).

PATIENTS AND METHODS

Twenty children underwent pneumonectomy procedures in both Thoracic Surgery Departments, Mansoura university hospitals (From January, 1995 to October 2002) and King Fahd Specialist Hospital, (from October 2002 – January 2004). There were 8 male (40%) and 12 female (60%) patients, the mean age was 6 years (range, 4 days to 15 years). There were 5 right sided and 15 left sided pneumonectomies.

The various indications for pneumonectomy in children in our series are mentioned in Table (I).

Most of our cases were elective 18 (90%) and only 2 cases (10%) were

urgent to control active bleeding. Routine chest roentgenograms (posteroanterior and lateral views), and high resolution chest CT scans were performed for all patients. Pre-operative (fiberoptic or rigid bronchoscopy) was done as a routine to all the patients as a part of the preoperative investigation and preparation or on table in emergency cases. Pulmonary function tests were not done to the patients in this age group.

SURGICAL PROCEDURE

All procedures were performed with the patients under general anesthesia with either a single lumen or double lumen tube. The patients were placed in the lateral position and formal posterolateral thoracotomy was the standard approach. The bronchial stump was closed by either polypropylene (Prolene) or Polyglactin (Vicryl), number 2/0 or 3/0 in two layers. The first layer was interrupted, and the second was continuous over and over. The bronchial stump was usually covered with intercostal muscles, pleural or pericardial flap. Single intercostal tube drainage was inserted as a routine to all our patients, and removed as early as possible postoperatively. Extubation was tried in the theatre and succeeded in 18 cases,

while 2 cases were shifted to the ICU intubated and ventilated. One case was a severely poly-traumatized patient with severe head injury and required ventilation for 1 week until the Glasco coma scale (GCS) improved and the patient was weaned safely, while the other case was a neonate with acquired bronchial stricture developed postpneumonectomy syndrome and required ventilation for 3 weeks.

RESULTS

We have a single case of intraoperative mortality (5%), in a severely injured patient, not related to the pneumonectomy procedure. We did not have any intra operative complication. Three immediate post operative complications occurred in 2 patients in our series (15%), they are shown in (Table II).

In One case there was a mild superficial infection of the anterior edge of the wound. It was treated with antibiotics and frequent dressing and completely cured and the patient discharged from the hospital within two weeks. The second two complications occurred in a neonate who developed acquired right main bronchial stricture due to prolonged intubation and ventilation. Right sided pneumonectomy was done to this

baby, and she was shifted to the ICU intubated and ventilated. In the first post-operative day, the patient developed acute pulmonary edema due to excessive IV crystalloids infusion. The condition was controlled with IV diuretics and restriction of IV crystalloids. We could not wean the patient off the ventilator, and her CXR showed severe ipsilateral shift of the mediastinum. Fig (1) CT was done and showed marked mediastinal shift to the right with over stretch of the left main bronchus Fig (2)

It was diagnosed as a post right pneumonectomy syndrome. Re-operation was done after 5 days from the initial surgery, and we inserted an expandable tissue prosthesis (rectangular type with remote accessory valve- Style 95 – volume 160cc) within the right thoracic cavity with the remote injection site in the subcutaneous tissue Fig (3, 4, & 5).

Within 3 weeks the patient was weaned completely off the ventilator and she was discharged from the hospital after 6 weeks. During the 2 years follow up of this patient, she was doing well, growing and re injection of the tissue expander was done only once. Follow up (average 3.5 years) of the other cases showed no delayed complications, with full growth and normal activities

Table (1) shows the various indications for pulmonary resections in our series.

Indication	No.	%
Inflammatory & Infective Lung Disease	10	50
End stage destroyed lung	6	30
Bronchiectasis	4	20
Acquired bronchial stenosis	3	15
Congenital Pulmonary Disease	2	10
CCAM type I	1	5
Congenital Lobar emphysema	1	5
Traumatic Lung Injury (to control massive hemothorax)	2	10
Tumors (Carcinoids)	2	10
Failed repair of ruptured left main bronchus	1	5

Table (II): Post-operative complications

Complications	No.	%
Superficial wound infection	1	5
Acute pulmonary edema	1	5
Post -pneumonectomy syndrome requiring re-operation	1	5

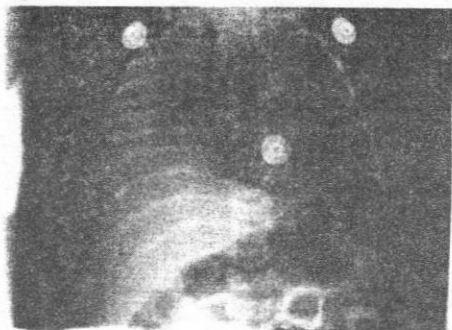

Fig (1). Postpneumonectomy chest roentgenogram shows extensive mediastinal shift to the right, with compensatory emphysema of the left upper lobe: Post-pneumonectomy syndrome

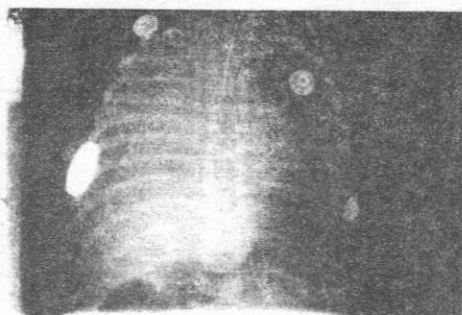


Fig (3). CXR shows correction of the mediastinal shift post insertion of a tissue expander in the right thoracic cavity.

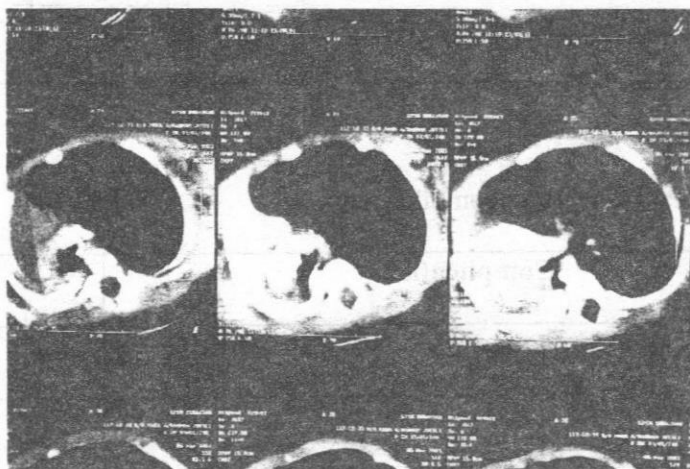


Fig (2). Postpneumonectomy CT chest shows extensive mediastinal shift to the right, compensatory emphysema of the left upper lobe, and stretching of the left main bronchus.

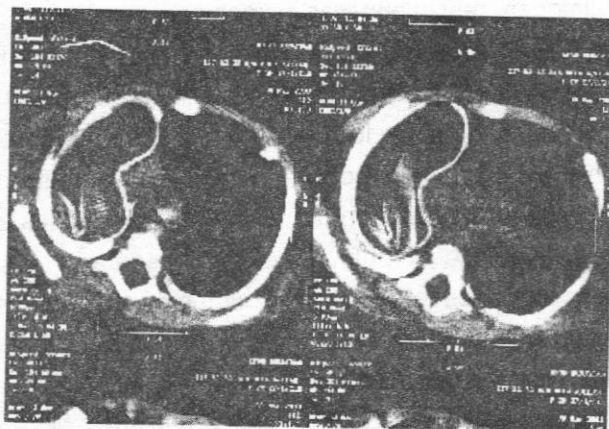


Fig (4&5). CT Chest shows correction of the mediastinal shift post insertion of a tissue expander in the right thoracic cavity.

DISCUSSION

There is relatively scanty information on pneumonectomy in children in the published literature and most of the reports were about mixed pulmonary resections in children or included with pneumonectomy in general. In this study we have included all the pneumonectomies done for patients < 15 years in age. It included our joint experience in two referral hospitals, MUH and KFSH. Regarding the indications for pneumonectomy, the major cause in this series was inflammatory and infective lung disease, 10 cases (50%). Six of our cases (30%) had an irreversibly destroyed lung, which was shrunken and consisted of

a bag of pus spilling on the other side. The other 4 patients (20%) had extensive unilateral bronchiectasis. In these 10 patients there was no evidence of active pulmonary TB. Most of the TB cases in children required limited pulmonary resections. In most of the published literature the main indications for pneumonectomy were bronchiectasis and lung destruction, often due to TB (10,17,20). With the introduction of anti TB drugs and the wide use of antibiotics the need of surgery for infective lung disease has much decreased in the developed countries (21,22). In another study done in our hospital (MUH) including all pulmonary resections in children conducted

between 1980 – 1995, the main indications for pulmonary resections was due to infective conditions (62%); of them 40% were bronchiectasis, and only 2% was TB cavity requiring localized resection (3). So pneumonectomy is rarely required for TB lung in children. The prevalence of pulmonary TB remains high in several areas of the world and pneumonectomy is often necessary to treat the disease (16,18). In the study done in South Africa by Blyth et al (2002) there were a high number of active pulmonary TB requiring pneumonectomies. In their study out of 59 pneumonectomies in children, 51 cases were due to destructive lung disease, of which 38 were bronchiectasis and 8 active pulmonary TB and 5 cases of end stage lung (5). Our results differ from Blyth et al, in that we did not have any case of pneumonectomy in children for pulmonary TB due to the better preventive measures and medical treatment in our locality.

Acquired bronchial stricture was the second commonest indication for pneumonectomy in our series, 3 cases (15%). In all three cases the stricture developed after prolonged intubation and mechanical ventilation for premature infants with hyaline mem-

brane disease. The initial CXR showed aeration of both lungs, but later there was a unilateral complete lung collapse. The lung distal to the obstruction was chronically infected. Repeated rigid bronchoscopes were done to these cases to remove granulation tissue and dilate the bronchus, but there was complete obliteration at the main stem orifice. Bronchial stricture is an uncommon problem in children and may be due the development of granulation tissue from repeated endobronchial suctioning. A true congenital bronchial stenosis is rare. Other causes of stricture were endobronchial TB(5, 23, 24, 25). Management can be difficult because of the small luminal diameter and proximity of lung parenchyma to the bronchial lesion. Bronchoplasty have obvious advantage over pneumonectomy in management of bronchial stenosis, but we did not attempt it (26).

Congenital pulmonary diseases occasionally require pneumonectomy, and usually managed by lesser pulmonary resections (3, 5, 10, 11, 12). We had 2 cases of congenital pulmonary abnormalities that required pneumonectomy, one case of congenital lobar emphysema involving both left

lung lobes and the other case was a congenital cystic adenomatoid malformation type I.

Blunt chest injuries due to motor car accidents were a common indication for limited resections in KFSH, but pneumonectomy was only required in 2 children. Pneumonectomy was indicated as there was life threatening massive hemopneumothorax from a severely lacerated lung which was impossible to repair. In studies of the surgical management of traumatic pulmonary injuries, including all ages, pneumonectomy was required in about 8% of the patients (13, 14). To our knowledge there were no reports concerned with the pneumonectomy for traumatic injuries in childhood.

Although tumors are rare in children, we had 2 cases of bronchial carcinoids. The first case was an 11 years old male patient and the second was a 12 years old female patient. In both cases the mass rose from the left main bronchus and totally obstructed it. There was a total left lung collapse. Bronchoplastic procedure was not appropriate as the lung distal to the obstruction was severely infected and impossible to re-expand.

Bronchial adenomas are considered the most common primary lung tumor in childhood (27). El-Saeid (1995) have reported 3 cases of bronchial carcinoids in children managed in MUH, but all required limited pulmonary resections.

Pneumonectomy was required in a case of failed repair of an avulsed left main bronchus after blunt chest trauma. Initially repair of the left main bronchus was done, but the child deteriorated and developed left lung collapse, fever and accumulated secretions. Patient was taken on the 4th postoperative day to perform pneumonectomy.

In our series there was a single intraoperative mortality (5%), in a severely injured 6 years old boy. He had severe head, chest and abdominal injury. He was hemodynamically unstable and had massive hemothorax. Pneumonectomy was done to control the bleeding but patient expired intraoperatively and CPR failed. Recently reported mortality rates of 0-5% have been reported (5, 16, 17, 28; 29). Although the mortality rates were low postpneumonectomy it was so high (69.7%) in a recent study concerning pneumonectomies in a group

of post traumatic pulmonary injuries (14).

Major complications in children are similar to those in adults. The three major life threatening intra operative complications are injury to a major vessel with massive hemorrhage, cardiac arrhythmias, and the development of a contralateral pneumothorax (1). These have not been seen in our patients. Pneumonectomy in children is easier to perform due to the elasticity of the pulmonary vessels and easier dissection. Post pneumonectomy complications, most commonly reported were empyema, bleeding, bronchopleural fistulae and wound sepsis (15, 16, 17, 18). Reports of morbidity rate of 23- 25% postpneumonectomy in children was recently published (5, 6) but they usually run a milder course and rarely complicated with bronchopleural fistula (5). In our study there were three immediate postoperative complications. One case of superficial wound sepsis, managed by antibiotics and daily dressings. The one life threatening postoperative complication was postpneumonectomy pulmonary edema. This was due to excessive infusion of crystalloids to the premature pneumonectomized and ventilated baby. It was managed

by IV diuretics and restriction of the fluids. Unfortunately this lethal complication has been reported to occur in 2-5% of cases of pneumonectomy (1). It is also frequently encountered post pulmonary resection in children, as it is so difficult to convince the ICU staff that pulmonary surgical patients do not require and should not be given the traditional amount of fluids needed by most other post surgical patients. Expansion and deflation of the lung, intraoperative barotraumas and volutrauma to the alveoli, and surgical manipulation all lead to the potential for pulmonary edema (30).

The third complication that occurred in the same patient was post right sided pneumonectomy syndrome. The baby developed marked rightward and posterior deviation of the trachea. Over distension of the left lung with its herniation into the right side of the chest and kinking of the left main bronchus. The patient was dependent on the ventilator and repeated trials of weaning failed. This rare complication has been reported in infants, children and infrequently young or middle aged adults. It most commonly develops after a right pneumonectomy, infrequently seen after a left pneumonectomy with a

right sided aortic arch and very rarely observed after a left pneumonectomy with a left sided aortic arch (1, 31, 32). Early diagnosis and mediastinal recentering are required for good outcome. Silastic implants and tissue expanders have been used with good results (Regnard et al, 1999; and Morell et al, 2002). We have reoperated the patient on the 5th postoperative day, and implanted a rectangular tissue expander with a remote injection site in the subcutaneous tissue. The position of the mediastinum has been re adjusted with salins injection into the prosthesis. The patient has been following up for 2 years with normal growth and good outcome.

CONCLUSION

Pneumonectomy for destroyed lung in children resolves complications and improves patient's quality of life. It is an easy procedure in children and usually not associated with severe complications like those in adults. The remaining lung expands to compensate for the loss of the removed lung and children tend to grow normally after pneumonectomy. It is essential to recognize and manage the complications that might occur as early as possible to improve the outcome.

REFERENCES

1. **Shields TW. General Features of Pulmonary Resection. In Thomas W. (2000) : Shields General Thoracic Surgery. 5thed. Lippincott Williams and Wilkins: Philadelphia, Baltimore, New York, London, Buenos Aires, Hong Kong, Sydney, Tokyo; pp. 375 – 384.**
2. **Shields TW and Ponn RB. Complications of Pulmonary Resection. In Thomas W. (2000) : Shields General Thoracic Surgery. 5thed. Lippincott Williams and Wilkins: Philadelphia, Baltimore, New York, London, Buenos Aires, Hong Kong, Sydney, Tokyo; pp. 481– 505.**
3. **El-Saeid MM. (1995) : Pulmonary Resection in Infants and Children: Indications and Complications. Ben. Med. J; 12 (1):65 – 77.**
4. **Mattioli G, Buffa P, and Granata C, Fratino G, Rossi G, Ivani G, Jasonni V. (1998) : Lung Resection In Pediatric Patients. Ped. Surg. Int; 13:**

10 -13 [Medline].

5. **Blyth DF, Buckels NJ, Sewsunker R, Soni MA. (2002) :** Pneumonectomy in Children. *Eur J Cardiothorac Surg*; 22 (4): 587 – 594.
6. **Eren S, Eren MN, Balci AE. (2003) :** Pneumonectomy in children for destroyed lung and the long-term consequences. *J Thorac Cardiovasc Surg*, 126 (2): 574-81.
7. **Haciibrahimoglu G, Fazlioglu M, Olcmen A, Gurses A, Bedirhan MA. (2004) :** Surgical management of childhood bronchiectasis due to infectious disease. *J Thorac Cardiovasc Surg*; 127 (5):1 361-1365.
8. **Lowe JE, Daniel TM, Richer C, Wolfe WG. (1980) :** Pulmonary Tuberculosis in Children. *J Thorac Cardiovasc Surg*; 80: 221- 25.
9. **Moran JF. (1990) :** Surgical Treatment of Pulmonary Tuberculosis. In Sabiston and Spencer Surgery of the Chest. 5thed. W.B. Saunders: Philadelphia, London, Toronto, Montreal, Sydney, Tokyo: 690 – 707.
10. **Campbell DN, Lilly JR. (1982) :** The Changing Spectrum of Pulmonary Operations in Infants and Children. *J Thorac Cardiovasc Surg*; 83: 680- 685.
11. **Ferguson TB Jr, Ferguson TB. (1990) :** Congenital Lesions of the Lung and Emphysema. In Sabiston and Spencer Surgery of the Chest. 5thed. W.B. Saunders: Philadelphia, London, Toronto, Montreal, Sydney, Tokyo. pp.: 762 – 814.
12. **La Quaglia MP. (2002) :** Congenital Anomalies in the Lung. In Thoracic Surgery. Edited by Pearson EG, Cooper JD, Deslauriers J, Ginsberg RJ, Hiebert CA, Patterson GA, Urschel HC Jr. 2nded. Churchill Livingstone: New York, Edinburgh, London, Philadelphia, pp. 499 – 519.

13. Carrillo EH, Block EF, Zeppa R, Sosa JL. (1994) : Urgent Lobectomy and Pneumonectomy. *Eur J Emerg Med*; 1 (3): 126 -30.
14. Huh J, Wall MJ Jr, Estrera AL, Soltero ER, Mattox KL. (2003) : Surgical management of traumatic pulmonary injury. *Am J Surg.*; 186(6): 620-4.
15. Conlan AA, Moyes DG, Schutz j, Scoccianti M, Abramor E, Levy H. (1986) : Pulmonary Resection In The Prone Position For Suppurative Lung Disease In Children. *J Thorac Cardiovasc Surg*; 92: 890 – 893.
16. Ashour M. (1997) : Pneumonectomy for tuberculosis. *Eur J Cardiothorac Surg.*; 12 (2): 209-13.
17. Blyth DF. (2000) : Pneumonectomy for inflammatory lung disease. *Eur J Cardiothorac Surg*;18(4):429-34.
18. Kim YT, Kim HK, Sung SW, Kim JH. (2003) : Long-term outcomes and risk factor analysis after pneumonectomy for active and sequels forms of pulmonary tuberculosis. *Eur J Cardiothorac Surg*; 23 (5): 833-9.
19. El –Saeid MM, El –Gamala AF, Khalaf SA, Gayed NL, Abdallah AK, Abulela SA, Abdullah FZ. (1994) : Complications of Pulmonary Resection: Mansoura Experience. *The Bulletin of the Egyptian Society of Cardiothoracic Surgery.*
20. Stiles QR, Meyer BW, Lindesmith GG, Jones JC. (1969) : The effects of Pneumonectomy in Children. *J Thorac Cardiovasc Surg.*; 58: 394 – 400.
21. Hausler M, Franke E, Wendt G, Kentrup H, Dohmen H, Kusenbach G. (1999) : Pneumonectomy In Cystic Fibrosis. *Pediatr Pulmonol*; 28: 376 – 379.
22. Langdale LA, Meissner M, Nolan C, Ashbaugh DG. (1992) : Tuberculosis and

- the Surgeon. *Am J Surg*; 163: 505 – 509?
- 23. Nagaraj HS, Shott R, Fellows R, Yacoub U. (1980) :** Recurrent Lobar Atelectasis Due To Acquired Bronchial Stenosis in Neonates. *J Pediatr Surg*; 15: 411- 415.
- 24. Touloukian RJ. (1996) :** Developmental Abnormalities of the Airways and Lungs. In Glenn's Thoracic and Cardiovascular Surgery. Edited by Baue AE, Geha AS, Hammond GL, Laks H, Naunheim KS. 6th ed. Appleton and Lange: London, Sydney, Toronto, Mexico, New Delhi, Tokyo, Singapore, Rio De Janeiro, New Jersey; 231-246.
- 25. Reynolds M. (2000) :** Congenital lesions of the lung. In Thomas W. Shields General Thoracic Surgery. 5thed. Lippincott Williams and Wilkins: Philadelphia, Baltimore, New York, London, Buenos Aires, Hong Kong, Sydney, Tokyo: pp.-952.
- 26. Prabhakaran K, Patankar JZ. (2004) :** Bronchoplasty for bronchial stenosis in a neonate: a case report. *J Pediatr Surg*; 39 (4): e6-8.
- 27. Hartman GE, and Shochat SJ (1983) :** Primary pulmonary neoplasms of childhood: A review. *Ann Thorac Surg*; 36 (1): 108-119.
- 28. Conlan AA, Moyes DG, Schutz J, Scoccianti M, Abramor E, Levy H. (1986) :** Pulmonary resection in the prone position for suppurative lung disease in children. *J Thorac Cardiovasc Surg*. Nov; 92(5):890-3.
- 29. Halezeroglu S, Keles M, Uysal A, Celik M, Senol C, Hacıbrahimoglu G, Arman B. (1997) :** Factors affecting postoperative morbidity and mortality in destroyed lung. *Ann Thorac Surg*; 64(6): 1635-8.
- 30. Cerfolio RJ. (2000) :** General Principles of Postoperative Care. In Thomas W. Shields

General Thoracic Surgery. 5th ed. Lippincott Williams and Wilkins: Philadelphia, Baltimore, New York, London, Buenos Aires, Hong Kong, Sydney, Tokyo, pp. – 516.

31. Wasserman K, Jamplis RW, Lash H, Brown HV, Cleary MG, Lafair J. (1979) : Post-pneumonectomy syndrome.

Surgical correction using Silastic implants. Chest; 75(1): 78-81.

32. Shamaji FM, Deslauriers J, Daniel TM, Matzinger FR, Mehran RJ, Todd TR. (1996) : Postpneumonectomy syndrome with an ipsilateral aortic arch after left pneumonectomy. Ann Thorac Surg;62(6):1627.

