



## THE PROTECTIVE ROLE OF ANTI-OXIDANT BETA-CAROTENE ON SCHISTOSOMA MANSONI INFECTED MURINE MICE

Saed Ruzik

*Tropical Medicine Department, Cairo Faculty of Medicine, AL-Azhar University*

Saleh Alebiary

*Tropical Medicine Department, Cairo Faculty of Medicine, AL-Azhar University*

Mohamed Bastawy

*Tropical Medicine Department, Cairo Faculty of Medicine, AL-Azhar University*

Mostafa Abou Alnga

*Anatomy and Embryology Department, Damietta Faculty of Medicine, AL-Azhar University*

Samy Zaky

*Tropical Medicine Department, Damietta Faculty of Medicine, AL-Azhar University*

*See next page for additional authors*

Follow this and additional works at: <https://mmj.mans.edu.eg/home>

---

### Recommended Citation

Ruzik, Saed; Alebiary, Saleh; Bastawy, Mohamed; Abou Alnga, Mostafa; Zaky, Samy; Alnoamany, Nabil; Hishmat, Mohamed; Tawfik, Mohamed; and El-Sayed, Ashraf Z. (2005) "THE PROTECTIVE ROLE OF ANTI-OXIDANT BETA-CAROTENE ON SCHISTOSOMA MANSONI INFECTED MURINE MICE," *Mansoura Medical Journal*: Vol. 34 : Iss. 1 , Article 1.

Available at: <https://doi.org/10.21608/mjmu.2005.127744>

This Original Study is brought to you for free and open access by Mansoura Medical Journal. It has been accepted for inclusion in Mansoura Medical Journal by an authorized editor of Mansoura Medical Journal. For more information, please contact [mmj@mans.edu.eg](mailto:mmj@mans.edu.eg).

---

## THE PROTECTIVE ROLE OF ANTI-OXIDANT BETA-CAROTENE ON SCHISTOSOMA MANSONI INFECTED MURINE MICE

### Authors

Saed Ruzik, Saleh Alebiary, Mohamed Bastawy, Mostafa Abou Alnga, Samy Zaky, Nabil Alnoamani, Mohamed Hishmat, Mohamed Tawfik, and Ashraf Z. El-Sayed

# THE PROTECTIVE ROLE OF ANTI-OXIDANT BETA-CAROTENE ON SCHISTOSOMA MANSONI INFECTED MURINE MICE

*By*

Saed Ruzik<sup>1</sup>, Saleh Alebiary<sup>2</sup>, Mohamed Bastawy<sup>3</sup>,  
Mostafa Abou Alnga<sup>4</sup>, Samy Zaky<sup>5</sup>, Mohamed G. Hishmat<sup>6</sup>,  
Mohamed M. Tawfik<sup>7</sup>, Ashraf Z. El-Sayed<sup>8</sup> and Nabil  
M.G. Alnoamani<sup>9</sup>.

*From*

*Tropical Medicine Department, Cairo Faculty of Medicine, AL-Azhar University<sup>1,2,3</sup>.  
Anatomy and Embryology Department, Damietta Faculty of Medicine,  
AL-Azhar University<sup>4</sup>. Tropical Medicine Department, Damietta Faculty of Medicine,  
AL-Azhar University<sup>5,9</sup>. Parasitology Department, Medical Research Institute,  
Alexandria University<sup>6</sup>. Tropical Medicine Department, Beni-Suef Faculty of Medicine,  
Cairo University<sup>7</sup>. And Zoology Department, Faculty of Science, Al-Azhar University<sup>8</sup>.*

## ABSTRACT

Schistosomiasis is the second most prevalent tropical disease in the world after malaria and is caused by the *Schistosoma*, genus of fluke. The pathophysiology of schistosomiasis is due to the immune response against the schistosome eggs. The clinical manifestations depend on the species of parasite, intensity of worm burden, and immunity of the person to the parasite. Many trials were done for production of vaccine against infection of schistosomiasis and many efforts were spent to prevent infection, but the rate of new cases is still high. On the other hand, we need a method to prevent or at least decrease the

inflammatory reaction caused by schistosomiasis. This study aimed to the evaluation of possible protective effect of anti-oxidant b-carotene on *S. mansoni* infected mice or decrease the inflammatory reaction caused by schistosomiasis. Sixty mice were included in this study and they were divided into 4 groups, every group is 15 mice: Group (1): (treated infected group); Group (2): (treated non-infected group); Group (3): (infected group) and Group (4): (normal control). The results: b-carotene reduced worm burden to about 20%. b-carotene significantly reduced hepatic and intestinal tissue egg load with a reduction percentage of 26% and

18% respectively. b-carotene normalized the serum enzyme AST that were elevated by schistosomal infection. b-carotene did not significantly change serum proteins both in infected and non infected animals. b-carotene exerted immunomodulatory effects on inflammatory reaction of hepatic schistosoma reflected as significant reduction in mean cellular infiltration diameter, more circumscription and less inflammatory cellular content, as well as more inflammatory reaction changes in schistosomal ova. We recommended further studies to judge the protective efficacy of b-carotene through histological study of animal skin and to judge its therapeutic efficacy if administered adjuvant with antibilharzial therapy.

## INTRODUCTION

Schistosomiasis is the second most prevalent tropical disease in the world after malaria and is caused by the *Schistosoma*, genus of fluke (7). In some parts of the world, it is also known as bilharzia in honor of Theodore Bilharz who is the first identified the etiological agent for *Schistosoma hematobium* in Egypt in 1851 (10).

Recent, World Health Organization (WHO) reports estimate that 500-

600 million people in 74 tropical and subtropical countries are at risk for schistosomiasis. Over 200 million people in these countries are infected. Of these, 120 million are symptomatic, with 20 million having severe clinical disease (16). In Egypt, schistosomiasis is not only a prime health problem, but it is also an economic one, as it affects millions of farmers at an early age, diminishing their productivity and exerting a serious socioeconomic problem.

The pathophysiology of schistosomiasis is due to the immune response against the schistosome eggs. The clinical manifestations depend on the species of parasite, intensity of worm burden, and immunity of the person to the parasite (15).

Many trials were done for production of vaccine against infection of schistosomiasis and many efforts were spent to prevent infection, but the rate of new cases is still high. On the other hand, we need a method to prevent or at least decrease the inflammatory reaction which could be caused by schistosomiasis.

$\beta$ -carotene, is an important micro-

nutrient with antioxidant capacity widely distributed in leafy vegetables, carrots and certain red and yellow fruits.  $\beta$ -carotene is a lipid soluble chain breaking antioxidant and is the most common carotenoid in food (26).  $\beta$ -carotene has been accepted to function as precursor of retinoic acid; quencher of electronically excited species such as singlet oxygen and antioxidant in tissues and plasma (32). Several studies have shown that  $\beta$ -carotene act as antioxidant (4), can enhance immune function independently of any provitamin activity (3), enhance epithelial integrity (35), has anti-inflammatory activity (27), and anti-cancer activity (anti-carcinogenesis) (24).

### AIM OF THE WORK

This study aimed to the evaluation of possible protective effect of antioxidant  $\beta$ -carotene on *S.mansoni* infected mice or decrease the inflammatory reaction caused by schistosomiasis.

### MATERIALS AND METHODS

Sixty mice were included in this study and they were divided into 4 groups, each group is 15 mice:

*Group (1)* : (treated infected group), the mice received b-

carotene 2mg/kg b. wt., daily for five consecutive days and then infected with  $80 \pm 10$  *S. mansoni* cercariae for each mouse.

*Group (2)* : (treated non-infected group), the mice were received b carotene 2mg/kg daily for five consecutive days.

*Group (3)* : (infected group), the mice infected with  $80 \pm 10$  *S. mansoni* cercariae, per-mouse.

*Group (4)* : (normal control), the mice representing non-infected non- treated.

Scarification of mice was done 9 weeks post infection.

The study included the following items:

- 1- Parasitology: study of worm burden and worm distribution in hepatic and intestinal vasculature, as well as tissue egg counting in hepatic and intestinal tissue.
- 2- Histological study of the different changes in both hepatic and intestinal tissue to study possible changes or modifications in schistosomal lesions and hepatic fibrosis.
- 3- Laboratory estimation of some liver function tests (serum total protein,

serum albumin, serum globulin, "ALT", and "AST") and Kidney function tests (serum urea).

## RESULTS

*In relation to the worm burden :*

The percentage of worms recovered from the liver of *S.mansoni* infected mice group 3 was reached 18.5%., while those recovered from portomesentric veins reached 81.5%. On the other hand, in the group (1) the percentage of worms in the liver was about 26.8% while the remaining is in the portomesentric tributaries and there was no hepatic shift occurred in group (1). In hepatic and intestinal vasculature, the mean number of worms was 24.8 worm/mouse in group (3) while in group (1) was 19.8 worm/mouse and there was a significant reduction between the two groups of mice ( $P.O.<.01$ ) by 20.2%. So, it was found that the worm burden is less in group (1) than in group (3). This reduction of worm burden was 20% and this is due to administration of b-carotene Table (1).

The number of schistosoma ova per gram liver tissue reached  $15-16 \times 10^3$  ova/g. tissue, while that of intestinal tissue was  $19-20 \times 10^3$  ova/gm. tissue in group (3), while in group (1) the ova count was  $11 \times 10^3$  ova/g liver and  $15-16 \times 10^3$  ova / g. intestine. So, in group (1), the tissue ova counts

significantly declined where the percentage of reduction reached about 18.02% and 26.7% in the intestine and liver respectively.

Table (2)

Laboratory estimation of serum proteins, globulin, A/G ratio are the same in both groups (1) and (3). b-carotene did not significantly change serum proteins in both infected and non infected animals. Table (3). Hepatic transaminases (ALT, AST) were significantly lower in group (1) than group (2) Table (4). Blood urea of group (3) was elevated than group (4). Blood urea of mice infected by *S. mansoni* cercariae was significantly ( $p>0.01$ ) elevated if compared with group (4) Table (5).

About the inflammatory cell formation and its effect on the egg; Regarding histological examination of hepatic sections 9 weeks post infestation, we found multiple periovular inflammatory cells in both portal tracts and hepatic lobules. The diameters of the inflammatory cells were less and occupied more restricted site in group (1) than in group (3). Table (6): showed that b-carotene exerted immunomodulatory effects on hepatic schistosomal inflammatory reaction reflected as significant reduction in mean inflammatory cell diameter.

**Table (1):** The effect of oral administration of  $\beta$ - carotene on the worm burden and worm distribution in infected *S. mansoni* mice

Animal Group	Mean No. of mouse worms	% of parasitic reduction	% of worm in liver	Mean n. of pairs	Worm distribution							
					Mean n. of worms		Liver			Intestine		
					Liver	Intestine	male	Female	couple	male	female	couple
Treated	19.8*	20.2	26.8	3.5	5.3	14.5*	3.5	1.8	0.8	8.2	6.3	3.5
Infected "Group1"	1.04			0.32	0.4	0.6	0.3	0.2	0.2	0.5	0.2	0.32
Infected "Group3"	24.8		18.5	4.1	4.6	20.2	2.8	1.8	0.4	10.5	9.7	4.1
	0.86			0.38	0.38	1.06	0.3	0.2	0.01	0.4	0.4	0.38

\* indicate highly significant ( $P < 0.01$ )

**Table (2):** The effect of oral administration of anti-oxidant  $\beta$ -carotene on the ova count in intestinal and hepatic tissue of infected mice.

Animal group	Intestinal ova count/g tissue		Hepatic ova count/g tissue		
	Mean	SE	Mean	SE	% reduction
Treated	15650.3*		11210.3*		
Infected "Group1"	492.5		275.4		26.8
Infected "Group3"	19114.4		15298.9		
	688.9		648.9		

Indicate highly significant  $P < 0.01$

**Table (3):** The effect of oral administration of anti-oxidant  $\beta$ -carotene on the serum protein, globulin, and A/G ratio, of infected *S. mansoni* mice.

Animal Groups	Protein gm / dL	Albumin gm / dL	Globulin gm / dL	Albumin / Globulin ratio
Group 1	5.06 $\pm$ 0.1	3.4 $\pm$ 0.1	2.5 $\pm$ 0.1	1.4 $\pm$ 0.1
Group 2	5.13 $\pm$ 0.1	3.3 $\pm$ 0.4	2.4 $\pm$ 0.2	1.5 $\pm$ 0.2
Group 3	6.1 $\pm$ 0.3	3.4 $\pm$ 0.06	2.8 $\pm$ 0.3	1.3 $\pm$ 0.1
Group 4	5.7 $\pm$ 0.1	3.4 $\pm$ 0.07	2.3 $\pm$ 0.2	1.5 $\pm$ 0.3



**Table (4):** The effect of oral administration of anti-oxidant  $\beta$ -carotene on hepatic enzymes of infected mice.

Animal groups	ALT Unit / ml	AST unit/ ml
Group 1	42.2 1.6*	32.7 2.2#
Group 2	38.4 1.7	34.8 1.9
Group 3	47.2+2.4*	48.05+2.5*
Group 4	36.2 1.6	33.6 2.05

- \*Indicate highly significant  $P < 0.01$  if compared with group (4).
- #Indicate highly significant  $P < 0.01$  if compared with group (1)
- Values are expressed as mean  $\pm$  S.E.

**Table (5):** The effect of oral administration of anti-oxidant  $\beta$ -carotene on the blood urea of infected mice.

Animal groups	Blood urea mg/dl
Group 1	49.01 4.6
Group 2	40.8 2.3
Group 3	56.3 2.8*
Group 4	39.9 1.9

- \* Indicate highly significant  $p > 0.01$ , if compared with group (4).
- Value are expressed as mean  $\pm$  S.E.

**Table (6):** The effect of oral administration of anti-oxidant  $\beta$ -carotene on the inflammatory cell diameter of infected mice .

Animal group	inflammatory cell diameter
Group 1	217.4 18.65*
Group 3	294.7 16.18

- \* Indicate highly significant ( $P < 0.01$ )
- Value are expressed as mean  $\pm$  S.E.



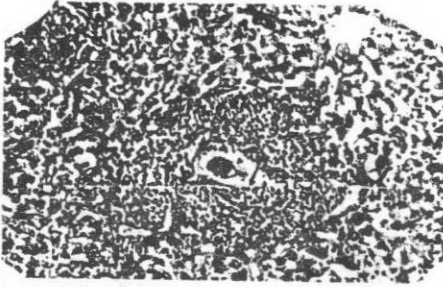


Fig. (1) : Hepatic section of infected mice for 9 weeks. Large cellular infiltration(IC) formed of densely packed inflammatory cells with irregular outline (arrow), surrounding intact ova ( head arrow) (with still nucleated miracidium).Hx and eosin stain (x 200).




Fig. (2): Hepatic section of infected mice treated by  $\beta$ -Carotene. Small area of cellular infiltration (CI) with regular outline (arrow)surrounding dead ova (head arrow). Hx and eosin stain (x200).




Fig. (3): Hepatic section of infected mice for 9 weeks.Note the following large fibrocellular infiltration (CI) in the peripheral area suarrounding dead ova (arrow) , central area of collagen fibers(CF), vacuolated hepatocytes (V) and ghosts of cells(g). Hx and eosin stain (x200)

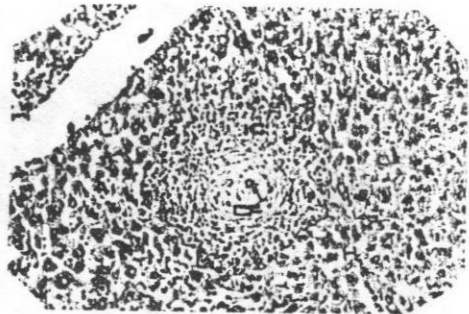


Fig: (4) Hepatic section of infected mice treated by  $\beta$ -carotene. Fibrocellular inflammatory cell(IC) smaller in size, with less inflammatory cells, small central area of collagen fibers(CF), partial improvement of hepatocytes(H) and small ova (arrow)in comparisone with Fig.(3). Hx and eosin stain (x 200).




Fig. (5): Hepatic section of infected mice treated by  $\beta$ -carotene. Note the following: small ova in terminal venule (arrow) and failure to develop cellular infiltration (CI) in hepatic parenchyma. Hx and eosin stain (x200).

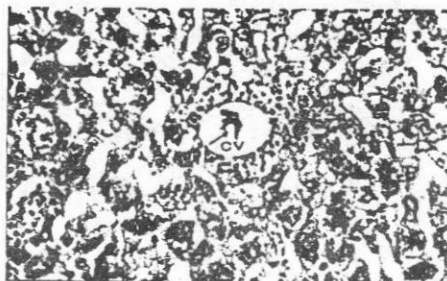


Fig. (6): Hepatic section of infected mice treated by  $\beta$ -carotene. Note the following: deformed ova (arrow), in the central vein (cv) with surrounding scanty cellular infiltration (CI), scattered inflammatory cells (head arrows) in between the hepatocytes. Hx and eosin stain (x 400).



Fig. (7): Section of small intestine infected mice for 9 weeks. Cellular infiltration (CI) developed in between the glands of the mucosal layer and areas of fibrosis (arrow). Masson trichrome stain (x 200).

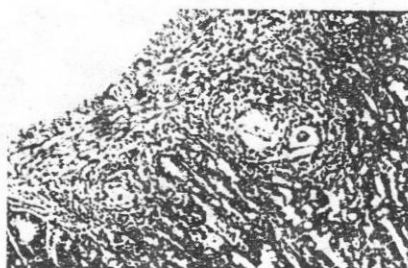


Fig. (8): Section of small intestine infected mice for 9 weeks. Multiple cellular infiltration (CI) developed in between the glands of the mucosal layer and fibrosis (F). Masson trichrome stain (x 400).

## DISCUSSION

As regards the worm burden and distribution, it has been widely demonstrated that the number of adult *S.mansoni* that can be recovered by portal perfusion is generally about 40-50% of the numbers of cercariae to which the host was exposed six or more weeks previously, however the sites of attrition of schistosomes that fail to mature has not been clearly established (20).

When the worms are affected by the presence of an extraneous chemical compound within the host, they release their hold on the walls of the host vessels and subsequently swept by the blood flow out of the mesenteric and hepatic vessels. If they are not seriously damaged by phagocytes they will be return to their normal sites, when the compound is withdrawn or excreted, this movement to and from the liver is termed as the hepatic shift, and it is reflected by abnormally high proportion of worms in the liver of the treated host (12), and is commonly used to detect and evaluate antischistosomal properties (30).

In this study, the worm burden was found less in group (1) than group (3). This may be attributed to

enhancement of skin integrity by b-carotene, that may retard or hinder cercarial skin penetration. The enhancement of gap junction intracellular communication by b-carotene was demonstrated by (35). There is physiological non-immune mechanism promote the resistance of animal models to infection with schistosomes such as skin thickness (31). Wagmann et. al., (1993) (33), showed that there is contribution towards resistance against schistosomes by immune response mediated by a number of different leucocytes including , macrophages, neutrophils , natural killer cell, T- and B-lymphocyte. On the other hand , mice deficient in B-lymphocyte have higher susceptibility to *S. mansoni* infection judged by increased egg tissue load and elevated mortality.

The percentage of worms recovered from the liver of *S.mansoni* infected mice group 3 was reached 18.5%, while those recovered from portomesentric veins reached 81.5%, these agree with that of (12) and (13) whom reported 80% and 84% respectively. In the present work this reduction in worm burden after carotene administration gives a very good

promising level of protection at the tested dose

As regard to schistosoma ova: By studying the intestinal and hepatic ova count, Abdel-Wahab, (1) concluded that each worm pair produces 300-3000 eggs daily for the duration of life span, which may reach 38 years. In the present work: egg counting in hepatic and intestinal tissues of group (1) is less than in group (3) with a statistical significant. So, carotene significantly reduced hepatic and intestinal tissue egg load with a reduction percentage of 26% and 18% respectively. The high proportion of ova in the intestinal tissue than in the liver may be due to increased proportion of pairing among schistosomes in the portomesentric tributaries and most of eggs actually trapped in the wall of large intestine rather than liver (13). The reduction in the ova count and its correlation with reducing number of worms was proved by (28) who concluded that any reduction in worm burden should be result in a corresponding decrease in the number of oviposition.

The results of serum proteins activity obtained in the present study revealed non significant changes in ser-

um total protein, albumin, and globulin in *S.mansoni* infected mice and control group. The same results were reported by (8). On the contrary, several studies demonstrated reduction in serum total protein in response to schistosomal infection in mice (2).

As regard Liver enzymes "ALT" and "AST", our results showed increased level in case of *S.mansoni* infected group (group 3) compared with normal control group. This could be attributed to liver cell damage and/or impaired permeability of cell membrane (9). Our results agree with that of (22) who reported the same results. Cha et al., (1980)(6) explained the elevated "ALT" and "AST" level being due to the heavy schistosome eggs deposition lodged in the micro vasculature of the liver.

The level of "ALT" and "AST" in the treated group did not show significant changes if compared with control group, these were explained by (21) who reported that carotene did not cause adverse side effect on hepatocyte.

On the other hand, the serum transaminase "AST" level has tendency for normalization in treated infect-

ed group (group 1) if compared with infected group (group3). This could be due to decrease in egg production and decrease in worm burden which were evidenced in parasitological part of this study. Konoplia et. al, (1996) (17) showed that carotene decreased the level of the biochemical signs of the hepatocyte injury and lowered or abolished the immunosuppressive effect of toxins. Also, there is immunomodulatory effect of carotene in toxic affection of the liver associated with blocking or retarding of entry of the suppressing substances to the vasculatures channel of the hepatocyte and \_carotene protects the cell against cytotoxicity and genotoxicity (18). EL-Shiekh et al., (1989) (11) reported a significant improvement in the level of serum transaminases (ALT and AST), the general health and nearly disappearance of clinical signs together with correction of nearly all the disturbed parameters of male Friesian calves with vitamin A deficient diet after given intramuscular injection of single dose of vitamin A at a rate of 10.000 unit per head of male Friesian calves.

The level of serum urea was found to be remarkably increased in

S. mansoni infected mice the

same results was recorded also by (22) who regarded that to the enhanced catabolism of tissue proteins and nucleic acid in schistosomal infected mice. It is well known that increased degradation of protein is followed by elevated blood urea. Also, antigen antibody complex in schistosoma infected mice was found to be accumulated in the glomerulus causing reduced filtration rate. Much improvement was achieved in serum urea in group (1) may be attributed to that b- carotene and vitamin A are necessary for enhancement of the metabolic processes of protein and non protein nitrogen compound (11).

The inflammatory reaction related to infection by S. mansoni is caused by the host cell mediated response against antigens from the parasite eggs, which results in hepatic and intestinal glaucomatous inflammatory reactions (29).

In this study, administration of beta-carotene in schistosoma mansoni infected mice resulted in hepatohistologically picture as:-

1- Significant reduction in mean inflammatory cell diameter, restricted site of inflammatory cell reaction and less inflammatory cellular content.

These immunomodulatory effect can be attributed to the anti-inflammatory activity of  $\beta$ -carotene (5), enhancement of T- lymphocyte proliferative response by beta-carotene (3), and to the anti-oxidant or anti-cytotoxicity activity of beta-carotene (18).

2- More inflammatory reaction in deposited schistosomal ova ; the site of antigen that trigger inflammatory response; such that some ova failed to induce inflammatory cell reaction , attacked by pigmented macrophage cells, and undergo inflammatory reaction while still in terminal venules. This reflects the anti-cytotoxic activity of b-carotene and its enhancement of phagocytosis of the macrophage cells that developed from either tissue histiocytes or peripheral blood monocytes, (3).

Several studies have shown that carotenoids can enhance immune function independently of any provitamin activity (3). The mechanism of immuno-enhancement may include the antioxidant singlet oxygen trapping capacities , enhancement of T- and B- lymphocyte proliferative response to mitogen , and increasing cytotoxic T- cell and macrophage tumor killing activity (3). Hoglent et al. (1997)(14) stated that large dose of vi-

tamin A enhances both Kupffer cell and peripheral monocyte cell function, i.e. phagocytosis. and consumption of carotenoid rich vegetable enhance N-K cell number as well as lymphocyte proliferation. There are several possibilities for the anti-inflammatory action of  $\beta$ -carotene, one of which involves the neutrophils which is not only a mediator , but also a promoter of inflammation (5). Beta carotene protects the cell against cytotoxicity and genotoxicity (18) . The upregulation of the activity of the phagocytic cells , Kupffer cells and peripheral blood monocytes may play a role in the vitamin A against chemical-induced liver injury (14).

**Summary:**  $\beta$ -carotene reduced worm burden to about 20%.b-carotene significantly reduced hepatic and intestinal tissue egg load with a reduction percentage of 26% and 18% respectively. $\beta$ -carotene normalized the serum enzyme AST that were elevated by schistosomal infection, the decline in "AST" after  $\beta$ -carotene was significant.  $\beta$ -carotene did not significantly change serum proteins both in infected and non infected animals.  $\beta$ -carotene exerted immunomodulatory effects on hepatic schistosomal histogenesis reflected



as significant reduction in mean inflammatory cell diameter, more circumscription and less inflammatory cellular content, as well as more inflammatory reaction in schistosomal ova.

**We recommended** further studies to judge the protective efficacy of  $\beta$ -carotene through histological study of animal skin and to judge its therapeutic efficacy if administered adjuvant with antibilharzial therapy.

## REFERENCES

- 1- Abdel - Wahab, M.F. (1982) : Schistosomiasis in Egypt. (CRC press Boce. Raton, Florida. USA) P.171.
- 2- Badawy A.A., Nada G.M., and Atef K.M. (1991) : Effect of parziquantel on hepatic murine Schistosomiasis: Histopathological study immunolocalization of type III Procollagen and serological analysis. Egypt. J. Bilh., 13:17-129.
- 3- Bendich A. (1994) : Role of antioxidants in the maintenance of immune functions: Frei., (3.ed.) Natural antioxidants in Human Health and Disease. Academic press, New York, P.447-467.
- 4- Burton G.W., and Ingold K.U. (1984) : Scavenging capacity of carotenoids in free radicals reaction. Science, 224: 565 - 573.
- 5- Camisa C., Eisenstat B., Ragas A., and Weissmam G. (1982) : The effects of retinoids on neutrophils function in vitro. J. Am. Acad. Dermatol., 6: 620- 629.
- 6- Cha Y.N., Byram J.E., Heine H.S., and Bueding E. (1980) : Effect of schistosoma mansoni infection on hepatic drug metabolizing capacity of a thymic nude mice. Am. J. Trop. Med. Hyg., 29 : 234 - 238.
- 7- Cirillo, R. L. (2002) : Schistosomiasis, Bladder. The form of schistosomiasis affecting the urinary tract involves Schistosoma haematobium. Last Updated: August 23, 2002.



- 8- Dewitt W.B., and Warren K.S. (1959) : hepatosplenic schistosomiasis in mice. Am. J. Trop. Med. Hyg., 8 : 440 -446.
- 9- El-Hiaeg M.O., AboulEnein M.M., Mustafa M.A., and Ibrahim I.A. (1978) : studies on certain serum enzymatic activities in hepatosplenic bilharziasis. Egypt. J. Bilh., 5 : 19 -28.
- 10- El-Garem AA (1998) : Schistosomiasis. Digestion Aug; 59 (5): 589 - 605 [Medline].
- 11- El-Sheikh M., Abdel-Rahim I.M., Ali G.M. and Ehrich J.H. (1989) : Renal function in Sudanese school children with schistosoma mansoni infection. Pediatr. Neph., 3 : 259 -264.
- 12- Foster R., Chee B.L., and Mesmer E.T. (1968) : The distribution of S. mansoni in the vertebrate host, and its determination by perfusion. J. Trop. Med. Hyg., 71 : 139-145.
- 13- Ghaleb H.A., shoeb H.A., El-Gawhary N., El-Borolossy A.W., El-Halawany S.A., and Madkour M.K. (1979) : characteristic feature of the oogram pattern and portal mesnteric adult worm load in experimental schistosoma mansoni infection in mice without treatment. J.Egypt. Med. Assoc., 62: 63 -76.
- 14- Hoglen N.C., Abril E.A., and Lantz R.C. (1997) : Modulation of Kupffer cell and Peripheral monocyte activity. Liver (3) : 157 -65.
- 15- King CH, Mahmoud AAF(1999) : Schistosomiasis. In: Guerant RL, Walker DH, Weller PF, eds. Tropical Infectious Diseases: Principals, Pathogen, & Practice. Vol 2. 1st ed. Philadelphia, Pa: Churchill Livingstone;; 1031-8.
- 16- Kogulan, P. and Lucey, D.R (2002) : Schistosomiasis. Last Updated. <http://www.emedicine.com/med/topic2071.htm>

- 17- Konoplia E. N., Prokopenko L.G., et al., (1996) : Immunomodulating and hepatoprotective action of retinoids in toxic liver involvement by Digalactosamine. Antibiotic Khimitor, 41 : 22.
- 18- Krinsky N.I. (1992) : Mechanism of action of biological antioxidants. PSEMB. 200: 248.
- 19- Krinsky N.I. (1993) : micronutrients and their influence on mutagenicity and malignant transformation. Ann. Acad. Sci., 686: 229 - 242.
- 20- Mangold B.L. and Dean D.A. (1983) : Autoradiographic analysis of *S. mansoni* migration from skin to lung in naive mice: Evidence that most attrition occur after the lung phase. Am.J. Trop. Med. Hyg., 32: 785-789.
- 21- McLaren D.S. (1979) : Cutaneous changes in nutritional deficiency. In Fitzpatrick, T.B., Eisen, A.Z., Wolff, Freberg, and Austen, K.F. (eds)
- 22- Metwally A. A., Janku I., Kemper Ebied F.A. and Botros S.S. (1990) : Effect of schistosomiasis infection on the clearance of phenazone in mice. Arzneim. Forsch. \ Drug Res., 40 : 206 -210.
- 23- Montenson M.A. and Golley D.G. (1999) : Resistance to infection in human and animal models. J. exp. Med. 189 : 637.
- 24- Mcreno F.S. and Jordo M.B. (1995) : Beta carotene and vitamin A effect on hepato carcinogenesis model. Inter. J. Vit. Nutr. Res., 65:87 -94.
- 25- Olivera D.N. and costa J. M. (1977) : *Schistosoma mansoni* : cholesterol ester profiles of plasma and liver in experimentally infected mice. Exp. Med., 189: 634 .
- 26- Olson J. A. and Kobayshi S. (1992) : Antioxdants in health and disease: overview. Proc. Soc1. Biol. Med., 200: 245.

- 27- Redlich C.A., Rockwell S., Chung J.S., et al., (1998) : Vitamin A inhibits radiation-induced pneumonitis in rats. *J. Nutr.* 128: 1661 -1664.
- 28- Secor W.E. (1996) : Pattern of worm and ova count in infected mice with *S. mansoni*. *J. Inf. Dis.*, 174: 1131.
- 29- Smithers S.R. and Doenoff M. (1982) : Schistosomiasis in immunology of Parasitic infections. Blackwell scientific Publications. P. 527 -607.
- 30- Standen O.D. (1953) : Experimental schistosomiasis. III. Chemo therapy and mode of drug action. *Ann. Trop. Med. Parasitol.* 47:26 :34.
- 31- Taveres-Neto J. and prata A., (1988) : Innate resistance to schistosomal infection. *Rev. Soc. Bra. Med. Trop.*, 21 : 131.
- 32- Tsuchiashi H., Kigoshi M., Iwatsuki M. and Niki E. (1995) : Antioxidants and carcinogenesis of B-carotene. *Arch. Biochem. Biophys.*, 323 , 137:145.
- 33- Wagmann T.G., Lin H Guilbert I. and Mosmann T.R. (1993) : Immune response to schistosomiasis. *Immunol., Today* 14 : 353.
- 34- Warren K.S., Mahmoud A.A., Cummings P., et al., (1974) : Experimental schistosomiasis. Why use experimental animals? *Am. J. Trop. Med. Hyg.*, 23:902.
- 35- Zhang L.X., Cooney R.V. and Bertram J.S. (1992) : Carotenoids up-regulate connexin-43 gene expression independent of their provitamin A or antioxidant properties. *Can. Res.*, 52: 5707-5712.

## تأثير مضاد الأكسدة بيتا كاروتين على العدوى بالبهارسيا المانسونى فى فئران التجارب

أ.د. سعيد رزيق<sup>١</sup> ، أ.د. صالح الابیاری<sup>٢</sup> ، أ.د. محمد بسطاوى<sup>٣</sup>

د. مصطفى أحمد أبو النجا<sup>٤</sup> ، د. سامى ذكى<sup>٥</sup>

د. محمد جمال حشمت<sup>٦</sup> ، د. محمد محمد توفيق<sup>٧</sup>

د. أشرف ذكى السيد<sup>٨</sup> ، د. نبيل النعمانى<sup>٩</sup>

قسم الأمراض المتوطنة - كلية الطب القاهرة - جامعة الأزهر<sup>٣,٢,١</sup> قسم التشريح والأجنة كلية الطب دمياط - جامعة الأزهر<sup>٤</sup>

قسم الأمراض المتوطنة - كلية الطب دمياط - جامعة الأزهر<sup>٥</sup> قسم الفتنيليات معهد البحوث الطبية جامعة الاسكندرية<sup>٦</sup>

قسم الأمراض المتوطنة - كلية الطب بنى سويف - جامعة القاهرة<sup>٧</sup> قسم علم الحيوان - كلية العلوم بالقاهرة - جامعة الأزهر<sup>٨</sup>

### الملخص العربى

استخدم فى هذا البحث ستون فأراً كلهم ذكور أوزانهم متساوية متشابهون فى ظروف المعيشة وتم تقسيم الفئران إلى أربع مجموعات : المجموعة الأولى : شملت (١٥) فأراً تم إعطائها بيتاكاروتين لمدة خمسة أيام متتالية قبل تعريضها للعدوى بسركاريا البلهارسيا المعوية المجموعة الثانية : (١٥) فأراً تم إعطائهم بيتاكاروتين فقط المجموعة الثالثة (١٥) فأراً تم تعريضهم للعدوى فقط بسركاريا البلهارسيا . المجموعة الرابعة (١٥) فأراً كمجموعة ضابطة بدون بيتاكاروتين أو التعرض للعدوى بالسركاريا . شمل البحث دراسة باراسيتولوجية وهستولوجية ودراسة كيميائية لوظائف الكبد . ولم يلاحظ أى تأثير ضار للبيتاكاروتين سواء فى المجموعات المصابة بالبلهارسيا أو التى لم تصب . ووجد أنه بالرغم من أن البيتاكروتين لم يمنع من العدوى بالبلهارسيا إلا أن فوائده تمثلت فى : انخفاض العدوى بالبلهارسيا المعوية بنسبة ٢٠٢% . تقليل عدد البويضات فى النسيج الكبدى والمعوى بنسبة ملحوظة ٢٦٨% و ١٨٥% على التوالى . انخفاض مستوى انزيمات الكبد الى المعدل الطبيعى . تقليل متوسط قطر أورام الحبيبات الكبدية وعدد الخلايا الالتهابية وكذلك

ضمور في بويضة البلهارسيا. وقد يعزى ذلك إلى أنه يحسن من فجوات الاتصال الخلوي الجلدي، يعوق اختراق البلهارسيا للجلد، له نشاط مضاد للالتهاب وتحسين تكاثر الخلايا الليمفاوية، له تأثير ضد تسمم الخلايا وتأثيره الداعم لجهاز المناعة ضد إصابة الكبد بالبلهارسيا ينعكس بتقليل حجم الحبيبات الكبدية وتقليل عدد الخلايا الالتهابية وانخفاض إنزيم أسبرتيت ترانس أميناز في الدم.

ونوصي بمزيد من الدراسات للحكم على تأثير البيتاكاروتين الوقائي من خلال دراسات هستولوجية لجلد الحيوان وأيضاً نوصي للحكم على كفاءته العلاجية لو أعطى مع أدوية علاج البلهارسيا .