



REPAIR OF ANAL STENOSIS: Y-V OR DIAMOND PEDICLE FLAP ANOPLASTY (COMPARATIVE RANDOMIZED STUDY)

Waleed Omar

Lecturer of General Surgery, Mansoura University Hospital . Mansoura Faculty of Medicine, Mansoura, Egypt

Follow this and additional works at: <https://mmj.mans.edu.eg/home>

Recommended Citation

Omar, Waleed (2005) "REPAIR OF ANAL STENOSIS: Y-V OR DIAMOND PEDICLE FLAP ANOPLASTY (COMPARATIVE RANDOMIZED STUDY)," *Mansoura Medical Journal*: Vol. 34 : Iss. 2 , Article 7.

Available at: <https://doi.org/10.21608/mjmu.2005.128243>

This Original Study is brought to you for free and open access by Mansoura Medical Journal. It has been accepted for inclusion in Mansoura Medical Journal by an authorized editor of Mansoura Medical Journal. For more information, please contact mmj@mans.edu.eg.

REPAIR OF ANAL STENOSIS: Y-V OR DIAMOND PEDICLE FLAP ANOPLASTY (COMPARATIVE RANDOMIZED STUDY)

By

Waleed Omar MD

From

Lecturer of General Surgery, Mansoura University Hospital .

Mansoura Faculty of Medicine, Mansoura, Egypt

ABSTRACT

Purpose :- Anal stenosis is a rare ,incapacitating, and challenging condition, occurring mainly after hemorrhoidectomy, for which several surgical techniques have been devised this comparative randomized study was carried out for patients with severe anal stenosis to evaluate the complication rate, recurrence of anal stenosis and long term outcome after Y-V and diamond pedicle flap anoplasty.

Methods :

In this study we reported 20 patients with severe postsurgical anal stenosis, 10 of them Underwent Y-V anoplasty while the other 10 had a diamond pedicle flap anoplasty .

Sixteen of 20 patients underwent unilateral anoplasty and the remain-

ing 4 patients underwent bilateral anoplasty . A Partial lateral internal sphincterotomy was performed in 16 patients who had a fibrotic muscular component contributing to stenosis All patients were seen every week until complete wound healing was achieved , then every 2 months for 6 months then every year after surgery with a mean follow up 28.6 ± 4.56 .

Results :

Early postoperative complications was moderate pruritis in one patient (10 %) who underwent diamond flap anoplasty, while temporary incontinence to gas and liquid stool in 20% , moderate pruritis in 10%, suture dehiscence in 10% and ischaemic contracture of the leading edge of the flap in 20% of cases who underwent Y-V anoplasty.

At one month follow up , all patients showed complete wound healing and most of them reported satisfactory results . Two months follow up one patient (10%) with diamond flap complained of mild constipation while 30% of patients with Y-V anoplasty complained of moderate constipation. Six months later neither further complications nor incontinence was observed and anorectal manometric studies revealed within normal resting and squeeze anal canal pressures for all patients . At one year follow up all patients with a diamond flap showed complete remission of their symptomatology and reported satisfactory results. While 70% of patients who underwent Y-V anoplasty judged their clinical results satisfactory and 30% of them had re-stenosis.

Conclusion :

Y-V and diamond flap anoplasty are two simple and safe methods for repair of postsurgical anal stenosis, however diamond flap anoplasty seems to be more safe and efficient method with good long term results.

INTRODUCTION

Anal stenosis is an uncommon and disabling condition, It represents an abnormal narrowing of the anal

canal to a varying extent due to stricture of the epithelial lining that has been replaced by fibrous connective tissue. (1) Although anal stenosis may occur without previous anorectal surgery , it usually results from surgical procedures carried out overzealously without the required technical knowledge, most commonly encountered as late sequelae of anorectal surgery. (2)

Stricture complicates approximately 5% to 10% of radical amputative hemorrhoidectomies and may be observed after other surgical procedures, such as internal sphincterotomy, fissurectomy, fistulectomy or excision of mucosal ectropion.(3) Patients with anal stenosis complain of constipation, decreasing caliber of stool, difficulty in initiating evacuation, incomplete evacuation, tenesmus or bleeding associated with a fissure.(4)

Effective management of anal stenosis is challenging. Symptomatic mild stenosis may be conservatively managed with diet changes, fiber supplements, and stool softeners. Many techniques have been described for the treatment of moderate to severe anal stenosis that is refrac-

tory to conservative treatment with good results reported in several series. (1,5,6,7,8). They include partial internal sphincterotomy with stricture release and several forms of plastic surgery through advancement and rotational flaps involving skin, mucosa or both. The surgical approach depends on the extent of stenosis as it may involve the skin, transitional zone to the dentate line, anal canal or all of these. (4)

In this comparative randomized study we present our findings in 20 consecutive patients treated for severe cicatricial anal stenosis who underwent Y-V anoplasty and diamond pedicle flap anoplasty evaluating the complication rate, recurrence of anal stenosis and efficacy as well as long term outcome.

PATIENTS AND METHODS

From December 2000 to March 2005, this prospective comparative randomized study was carried out, it included 20 patients, and they were 15 men and 5 women with a mean age 37.45 ± 8.26 years (range 26 - 52 years). All patients had severe anal stenosis causing obstructive symptoms that would not admit the exam-

ining finger and much pain that Hegar dilators could not be tried.

Hemorrhoidectomy was the most frequent cause for anal stenosis (17 patients), fistulectomy (2 patients) and fissurectomy (one patient) (table 1).

Two surgical procedures were used, Y-V flap anoplasty (10 patients) and diamond shaped pedicle flap anoplasty (10 patients). According to the classification proposed by Milson and Mazier 1986⁽⁹⁾, all patients had severe anal stenosis complained of constipation in the 20 patients, frequent episodes of bleeding in 14 patients, painful evacuation in 18 patients, and chronic laxative use in 13 patients (table 2). Randomization was performed using computer-generated series of random numbers. The time elapsed from anal surgery to anoplasty varied from 7 months to 6 years. Depending on the degree of stenosis, patients initially underwent either unilateral anoplasty (8 in Y-V flap and 8 in diamond pedicle flap) or bilateral anoplasty (2 in Y-V flap and 2 in diamond pedicle flap) if the anus was still tighter than desired.

Patients were admitted before sur-

gery for mechanical bowel preparation and assessment for any associated medical peri-operative risk factors.

SURGICAL TECHNIQUE

Surgery was performed with the patient in lithotomy position (Fig. 1) after Foley's catheter placement, general or spinal anesthesia was administered. Intravenous third generation cephalosporin (1 gm) and metronidazole (500 mg) were administered to each patient. The fibrous scar tissue involving the anal canal and mucocutaneous junction was radially incised laterally and care was taken to avoid injuring the cutaneous fibers of the superficial external anal sphincter. A partial lateral internal sphincterotomy was performed in patients who had a fibrotic muscular component contributing to the stenosis, the extent of which varied according to the longitudinal length of the scar, then the anus was gradually dilated after scar incision.

In a diamond shaped skin flap technique, a diamond shaped composite flap of skin and subcutaneous fat as described by Caplin and Kodner 1986 (10) was sharply elevated and advanced into the anal canal de-

fect, tension was eliminated by dividing the filmy fibrous septae at the margins of the pedicle (Figs.2 & 3).

Utmost care was taken to avoid undermining the pedicle of fat that contains the perforating blood vessels to the skin; the flap was designed such that the leading half of the flap is approximately the same size as the defect that resulted after scar incision. The leading edge of the flap was sewn to mucosa with simple 3/0 vicryl suture (Fig. 4). The posterior edges were approximated also with 3/0 vicryl sutures (Fig. 5).

In Y-V anoplasty, a Y-shaped incision that starts in the anal canal with the two limbs of the Y extending out into the perianal skin laterally, a full-thickness triangular skin flap with 1 to 2 mm of subcutaneous fat was mobilized (Figs. 6&7). of importance to keep the flap wide to minimize the risk of loss of the flap secondary to ischemic necrosis. The leading edge of the flap should be as wide as the defect created after scar incision and dilatation. The length of the flap was approximately four times the width of the leading edge and the base at least equal to the length. The angled leading edge of the flap was approxi-

mated to rectal mucosa at the mucocutaneous junction (dentate line) with 3/0 vicryl sutures. The lateral perineal cross limb of the Y was approximated under minimal tension with interrupted simple 3/0 vicryl sutures.

Postoperatively, patients received nothing by mouth for two days, the diet was then advanced over 3 day period and a high fiber diet combined with bulk laxatives was recommended. Intravenous antibiotics were continued every 12 hours for two days after which oral metronidazole (500 mg/6h) was taken for another 5 days.

Patients were not allowed to sit for about 4 days after operation to avoid vascular compromise to the flap then sitz baths were initiated and cleaning of the perianal region was recommended. Postoperative stay ranged 3-9 days with a mean of 5.2 ± 1.47 days. After patients discharge they were followed up every week until complete wound healing was achieved, then every 2 months for 6 months and then every year after surgery with a total follow up range 12-42 months (mean 28.6 ± 4.56) An attempt was made to follow each patient annually during the study period. At six months postoperatively, anorec-

tal manometry was done for all patients using water -perfused catheter applying a continuous and stepwise pull-through technique (Sandhil Biolab Central Unit Manometry) with evaluation of maximum resting pressure(MRP)and maximum squeeze pressure (MSP). The complication rate , recurrence of anal stenosis requiring re-operation during the study period was assessed.

RESULTS

In our series 10 patients underwent Y-V anoplasty, and 10 patients had a diamond-shaped pedicle flap . 16 of 20 patients had concomitant lateral internal sphincterotomy and 4 of 20 patients underwent bilateral procedures (2-Y-V and 2 diamond flap). Temporary incontinence to gas and liquid stool lasting up to 2 months was observed in 2 patients who underwent Y-V anoplasty, moderate pruritis that subsided after 3 weeks was observed in 2 patients (one with Y-V and one with diamond flap).

The mean time until complete wound healing was 4.75 ± 1.7 weeks, varying from 3 to 6 weeks. Complete wound healing was observed in all patients. In the patients who underwent Y-V anoplasty, suture dehisc-

cence in one patient (10%) and 2 patients (20%) experienced an ischemic contracture of the leading edge of the flap (table 3) . At one month follow up all patients showed a complete healing of the wound and most of them reported satisfactory results with alleviation of the their preoperative symptoms such as painful evacuation and bleeding . At 2 months follow up, one patient (10%) with a diamond pedicle flap complained of mild constipation and 3 patients (30%) with Y-V anoplasty complained of moderate constipation, on digital examination, the anal canal of all patients was wide enough and assumed a good elasticity. Six months later neither incontinence nor any further complications was observed and anorectal manometry revealed normal both resting and

squeeze anal canal pressures for all patients (table 4).

At one year follow up, all patients with a diamond pedicle flap had a complete alleviation of their symptomatology and reported a satisfactory result. Among 10 patients who underwent Y-V anoplasty, 7 patients (70%) judged their clinical results satisfactorily, while 3 patients (30%) developed constipation that did not improve with periodical use of anal dilators, those 3 patients were the same who experienced the postoperative complication (one suture dehiscence and 2 ischemic contracture of the leading edge of the flap). and later on developed re-stenosis on digital examination , and re-operation was done for them.

Table (1): Causes of anal stenosis in our study.

Causes	No. of cases	%
Hemorrhoidectomy	17	85%
Fistulectomy	2	10%
Fissurectomy	1	5%

Table (2): preoperative symptoms in patients with anal stenosis and rate of occurrence.

Complaints	No.
Constipation	20 (100%)
Painful evacuation	18 (90%)
Bleeding	14 (70%)
Chronic laxative use	13 (65%)

Table (3): postoperative complications in our study.

Type of operation	Early Postoperative				2 months postoperative		One year postoperative
	Incontinence gas & liquid	Pruritis	Suture dehiscence	Isch. contracture	Mild constipation	Moderate constipation	restenosis
Y-V anoplasty	2(20%)	1(10%)	1(10%)	2(20%)	-	3(30%)	3(30%)
Diamond shaped pedicle flap anoplasty	-	1(10%)	-	-	1(10%)	-	-

Table (4): postoperative manometric studies in our patients.

Operation	Maximum resting pressure (mean)	Maximum squeezing pressure (mean)
Y-V anoplasty	54 ± 6.2 mmHg	160 ± 7.2 mmHg
Diamond flap anoplasty	59 ± 2.3 mmHg	166 ± 5.2 mmHg

Table (5): summary of literature review of anoplasty operations for anal stenosis.

Author, year	Technique	No. of cases	Mean follow-up (months)	Good results
Gonzalez et al ⁽¹¹⁾ , 1995	S-plasty and advancement flaps	17	18	94%
Anglechik et al ⁽³⁾ , 1993	Y-V anoplasty or diamond flap	14	12	100%
Maria et al ⁽⁵⁾ , 1998	Y-V anoplasty or diamond flap	42	24	93%
Oh & Zinberg ⁽⁸⁾ , 1982	C-plasty	12	12	92%
Caplin & Kodner ⁽¹⁰⁾ , 1986	Diamond flap	7	Nr *	100%
Gingold & Arvanitis ⁽¹³⁾ , 1986	Y-V	14	Nr *	100%
P... et al ⁽¹⁴⁾ , 1990	Island flaps U or diamond	25	19	92%
Sentovich et al ⁽¹⁵⁾ , 1996	House flap	21	28	90%
Khubchandani ⁽¹⁶⁾ , 1985	Mucosal flap advancement	53	Nr	94%

* Nr = Not reported.

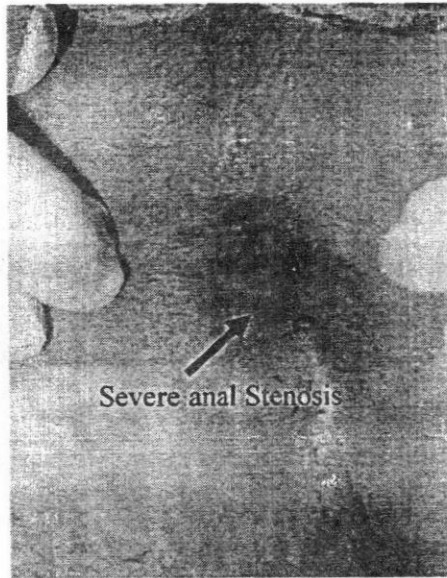
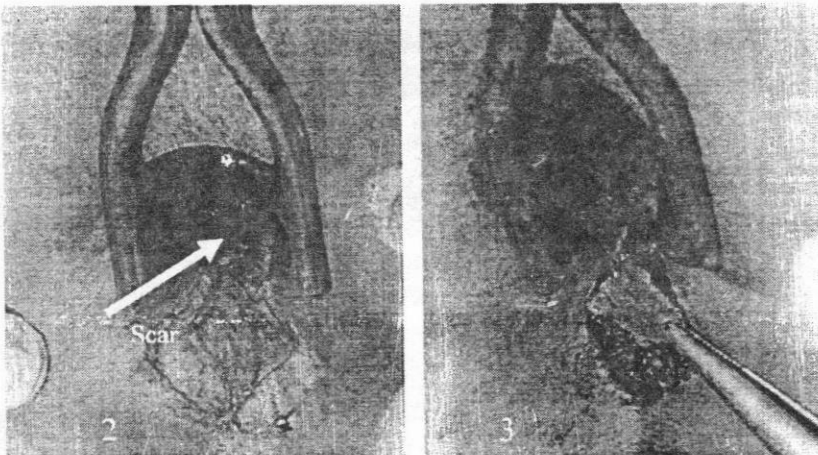


Fig. 1 : pre operative anal stenosis in lithotomy position



Figs. 2 & 3 : Creation of a diamond flap and its mobilization

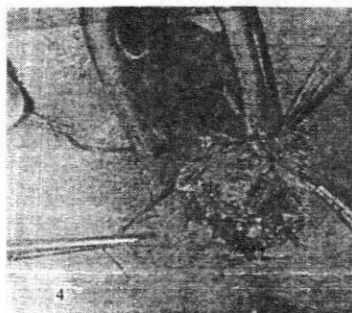
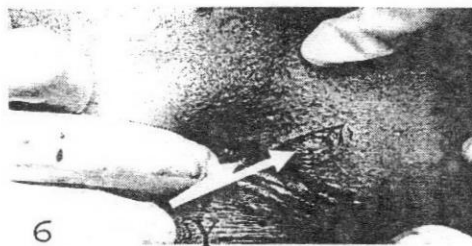


Fig. 4 : Suturing of the leading edge of the flap to the rectal mucosa

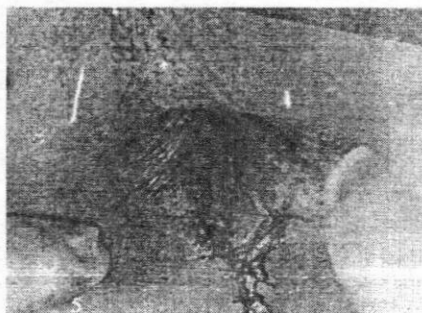

Fig .5 : Diamond flap after advancing into anal canal



Figs 6 & 7: creation of the flap and its mobilization with 1 to 2 mm of subcutaneous fat

DISCUSSION

Anal stenosis is one of the most feared and disabling complications of anorectal surgery. Most cases of mild to moderate narrowing can be managed conservatively with high fiber diet, bulk laxatives and anal dilations. Nevertheless, when conservative treatment is not effective in facilitating evacuation and reducing pain, surgical treatment is warranted.

A number of corrective surgical procedures have been designed aiming to bring a healthy lining to the narrowed portion of the anal canal. (5) Since more complex techniques such as S-plasty (11) have now been abandoned due to high morbidity and long hospital stay. Easier techniques are still being performed with good results (table 5). The majority of surgical procedures for the treatment of anal canal stenosis involve excision of the scar, partial internal sphincterotomy and re-shaping of the transitional zone and perianal skin with skin advancement flaps of various modification such as Y-V, V-Y, Island, house and rotational flaps (1, 5, 10,12). Such flaps obtain their vascular supply from unnamed vessels present either in the subdermal vascular plexuses or subcutaneous tissue(2).

The ideal procedure for repair of anal stenosis should be simple, leads to no or minimal early and late morbidity, good patient acceptance and restore anal function with a good long-term outcome. In patients with a moderate degree of stenosis, a single sphincterotomy may be a sufficient treatment, however, when fibrosis is intense, it might be an obstacle to the physiologic anal dilation occurring during evacuation, indicating the need for the interposition of normal tissue. All patients we treated had severe anal stenosis and dilation was not possible and we did not agree with the use of dilation under anesthesia because of the possible complications (9).

In the current study, we reported the results of 20 patients with post surgical anal stenosis treated with Y-V anoplasty (10 patients) and diamond shaped flap anoplasty (10 patients). The mean duration of follow up was 28.6 ± 4.56 months.

Flap necrosis, suture line dehiscence, donor site problems, local sepsis, ischemic contracture of the leading edge of the Y-V flap, fecal incontinence and re-stenosis are possible complications of skin advance-

ment flaps. (4,5) In the current study, 6 of 10 patients who underwent Y-V anoplasty had experienced early postoperative complications and 3 of them had re-stenosis after one year. This can be explained by the fact that their stenosis was long reaching to the level of the dentate line, the Y-V flap receives its blood supply through the skin and not from unnamed vessels extending through a fatty pedicle from the underlying tissue and the leading edge of the flap was not wide enough as the created defect after scarotomy so that, being more prone to be under tension and so liable to suture line dehiscence and ischemic contracture of the leading edge. Good results have been reported with the use of this technique when used for strictures below the dentate line. (13)

It was reported that, the diamond shaped flap anoplasty has several advantages; simplicity of construction, maintenance of maximal blood supply to the flap, minimal tension on the suture line and allowing for primary closure of the donor site. (10) Island or house-shaped flaps, derived from diamond flap, have been proposed with good results. (14-15)

In this study, all patients who had diamond shaped flap anoplasty reported satisfactory results with a long term follow up. These good results were also reported by Caplin and Kodner (1986) and Angelchick et al. (1993) with good results in 100% of their cases.

In conclusion, Y-V and diamond shaped flap anoplasty are two simple and safe methods to correct post surgical anal stenosis. On the basis of our findings and in accord with the published literature, diamond flap anoplasty appears to be safe, efficient and seems to offer a more satisfactory repair because of the better mobilization of the flap, less tension on the suture line and less incidence of ischemic flap retraction, so being a reproducible method to apply regardless of the level of stenosis.

REFERENCES

- (1) Gonzalez AR, de Oliveira O, Verzaro R, Noguerras J, Wexner SD. (1995) : Anoplasty for stenosis and other ano-rectal defects. *Am Surg*; 61:526-9.

- (2) **Lieberman H, Thorson AG. (2000)** : How I do it . Anal stenosis. Am J Surg ; 179:325-9.
- (3) **Angelchik PD, Harms BA, Starling JR. (1993)** : Repair of anal stricture and mucosal ectropion with Y-V or pedicle flap anoplasty. Am J Surg; 166 (1). 55-9.
- (4) **Rakhmanine M, Rosen L, Khubchandani I, Stasik J , Riether RD. (2002)** : Lateral mucosal advancement anoplasty for anal stricture. Br J Surg; 89: 1423-24.
- (5) **Maria G, Brisinda G, Civello IM. (1998)** : Anoplasty for the treatment of anal stenosis. Am J Surg; 175: 158-60.
- (6) **Rosen L. (1988)** : Anoplasty. Surg Clin North Am; 68:1441 - 6.
- (7) **Luchtefeld M. (2001)** : Anal stenosis. problems in General surgery; 18 (3): 17-23.
- (8) **Oh C, Zinberg J. (1982)** : Anoplasty for anal stricture . Dis colon Rectum; 25:809-10.
- (9) **Milson JW, Mazier WP. (1986)** : Classification and management of post surgical anal stenosis. Surg Gynecol obstet.; 163: 60-4.
- (10) **Caplin DA, Kodner IJ. (1986)** : Repair of anal stricture and mucosal ectropion by simple flap procedure . Dis colon Rectum; 29:92 -4.
- (11) **Hudson AT. (1967)** : S-plasty repair of whitehead deformity of the anus. Dis colon Rectum; 10: 57-60.
- (12) **Khubchandani IT. (1994)** : Anal stenosis. Surg. Clin North Am.; 74: 1353-60.
- (13) **Gingold BS and Arvanitis M. (1986)** : Y-V anoplasty for treatment of anal stricture. Surg Gynecol Obstet.; 162 (3): 241-2.
- (14) **Pearl RR, Hooks VH, Abcarian H. (1990)** : Island flap ano-

plasty for the treatment of anal stricture and mucosal ectropion. *Dis Colon Rectum*; 33: 581-3.

(15) **Sentovich SM, Falk PM, Christensen MA.** (1996) : Opera-

tive results of House advancement anoplasty . *Br J Surg* 1996; 83: 1242-4.

(16) **Khubchandani IT .** (1985) : Mucosal advancement anoplasty . *Dis Colon Rectum*; 28: 194-6.

إصلاح الضيق الشرجى باستخدام شريحة Y-V أو الشريحة المعينة (دراسة مقارنة عشوائية)

د. وليد حسن عمر

مدرس الجراحة العامة - كلية الطب - جامعة المنصورة

الملخص العربي

يعتبر الضيق الشرجى للقناة الشرجية من المضاعفات نادرة الحدوث والصعبة بعد جراحات الشرج وغالباً ماتحدث بعد عمليات إستئصال البواسير الشرجية. ويوجد أكثر من طريقة جراحية لعلاجها. تم هذا البحث باستخدام المقارنة العشوائية وتم تقييم النتائج باستخدام شريحة Y-V والشريحة ذات الشكل المعين من حيث نسبة حدوث المضاعفات ونسبة إرتجاع الضيق الشرجى والنتيجة الكلية على المدى البعيد. إحتوى هذا البحث على عدد (٢٠) مريض ومريضة وقد تم عمل شريحة Y-V لعشرة من المرضى والعشرة الآخرين تم عمل شريحة ذات الشكل المعين. وقد استخدمت هذه الطريقة على جانب واحد من الشرج مع عمل قطع جزئى للعضلة الشرجية الداخلية فى (١٦) مريض.

تم متابعة المرضى كل أسبوع ثم كل شهرين لمدة ستة أشهر ثم سنوياً بعد ذلك. وكانت المضاعفات الأولية من مرضى الشريحة Y-V عدم تحكم مؤقت للغازات والبراز السائل فى إثنان من المرضى وحكة شرجية متوسطة فى مريض واحد وعدم التئام فى الجرح فى مريض واحد وقصور بالدورة الدموية بطرف الشريحة المتقدم فى إثنان من المرضى. أما فى مرضى الشريحة المعينة كان هناك حكة شرجية متوسطة فى مريض واحد. بعد شهر من المتابعة الأولية كان هناك إلتئام تام للجرح والنتائج مرضية فى معظم المرضى. وبعد شهرين من المتابعة كانت الشكوى على هيئة إمساك بدرجة طفيفة فى مريض واحد من مرضى الشريحة المعينة ودرجة متوسطة فى ثلاثة من مرضى الشريحة Y-V .

وبعد ستة أشهر أسفرت المتابعة عن عدم وجود أية مضاعفات أخرى وقد أظهرت دراسة حركية القناة الشرجية معدلات طبيعية لضغوط العضلة القابضة للشرج أثناء الراحة وأثناء الإنقباض. وبعد سنة من متابعة المرضى كانت النتائج كالآتي :-

- مرضى الشريحة المعينة تم معافاتهم نهائياً من شكواهم وكانت النتائج جيدة.
- مرضى الشريحة Y-V كانت النتائج مرضية في ٧٠٪ منهم وظهر إرتجاع للضيق الشرجي في ثلاثة مرضى

وبناءً عليه فإن إستخدام طريقتي الشريحة المعينة والشريحة Y-V في إصلاح الضيق الشرجي هما طريقتان بسيطتان وأمنتان ولكن من حيث النتائج فطريقة الشريحة المعينة هي أكثر أمناً وكفاءة ونتائجها جيدة على المدى البعيد .